Non-traumatic chest in the emergency room

Poster No.: C-0979

Congress: ECR 2010

Type: Educational Exhibit

Topic: Chest

Authors: J. F. Costa, P. Marques, P. Donato, A. Costa, L. Teixeira, F. Caseiro-Alves; Coimbra/PT

Keywords: Chest, Emergency, MDCT

DOI: 10.1594/ecr2010/C-0979

Learning objectives

The major teaching points of this exhibit are:

1) To recognize the characteristic imaging findings associated with the most frequent conditions presenting with acute thoracic pain.

2) To provide a structured framework for developing a differential diagnosis.

Background

Patients who present to the emergency department with chest pain constitute a common and important diagnostic challenge because of extensive etiology that ranges from benign to potentially lethal. MDCT has been shown to be effective for the delineation of many causes of chest pain that may be unapparent on initial clinical or radiographic evaluation.

Imaging findings OR Procedure details

Acute chest pain in the absence of trauma remains a diagnostic challenge because it encompasses a wide spectrum of cardiac and noncardiac disease.

Although accurate clinical history and physical examination are essential, diagnostic imaging continues to be indispensable in helping physicians to navigate nonspecific signs and symptoms and reach a more refined assessment.

The initial approach to evaluating chest pain includes excluding life-threatening causes, such as:

- Acute coronary syndrome,
- Acute aortic syndrome,
- Pulmonary embolism,
- Pneumothorax,

- Pneumomediastinum,
- Pericarditis

1) Acute coronary syndrome

Acute coronary syndrome (ACS) is a spectrum of acute myocardial ischemia that spans acute myocardial infarction and unstable angina.

Chest pain or discomfort is the most common presenting complaint in patients who have ACS. The biomarkers that can be detected do not aid in the diagnosis of unstable angina, which accounts for roughly half of all cases of ACS.

Information about the presence and extent of coronary artery disease can substantially improve the clinical care and management of patients with acute chest pain. With very short examination times of approximately 5 minutes and robust image quality, multidetector cardiac CT constitutes a highly attractive approach for initial work-up in the emergency department setting.

In most patients (80%-94%) with an acute coronary syndrome, a significant coronary artery stenosis can be detected with selective coronary angiography. High levels of diagnostic accuracy also have been established for the detection of significant coronary artery stenosis with the use of 16- and 64-section multidetector computed tomography. However, the results of observational studies demonstrate that a myocardial infarction also may occur in patients with coronary luminal narrowing of less than 50%.

Fig.: Post-processed views (global VRT and curved multiplanar reformat) of the coronary arteries demonstrate extensive calcified plaque and subtle noncalcified plaque in the left anterior descending and right coronary arteries. The stenoses were confirmed on cardiac catheterization and the patient received a coronary artery bypass. ***References:*** J. F. Costa; Radiology, Hospitais da Universidade de Coimbra, Coimbra, PORTUGAL

In addition, hemodynamically nonsignificant lesions with a thin fibrous cap and a large underlying lipid core may be more likely than other lesions to rupture.

Fig.: Significant stenosis of the right coronary artery in a 67-year-old patient with unstable angina and multiple risk factors. Curved multiplanar reformatted image of the right coronary artery demonstrates a high grade stenosis (arrow) in the middle segment of the artery.
References: J. F. Costa; Radiology, Hospitais da Universidade de Coimbra, Coimbra, PORTUGAL

Investigators in a few studies have evaluated the utility of electron-beam CT-based detection of coronary artery calcification for predicting the likelihood of acute coronary syndromes in patients with acute chest pain. The results of these studies demonstrated that the diagnostic value of a finding of coronary calcification is controversial. Especially in young patients, the absence of coronary calcification may not imply the absence of coronary atherosclerotic plaque.

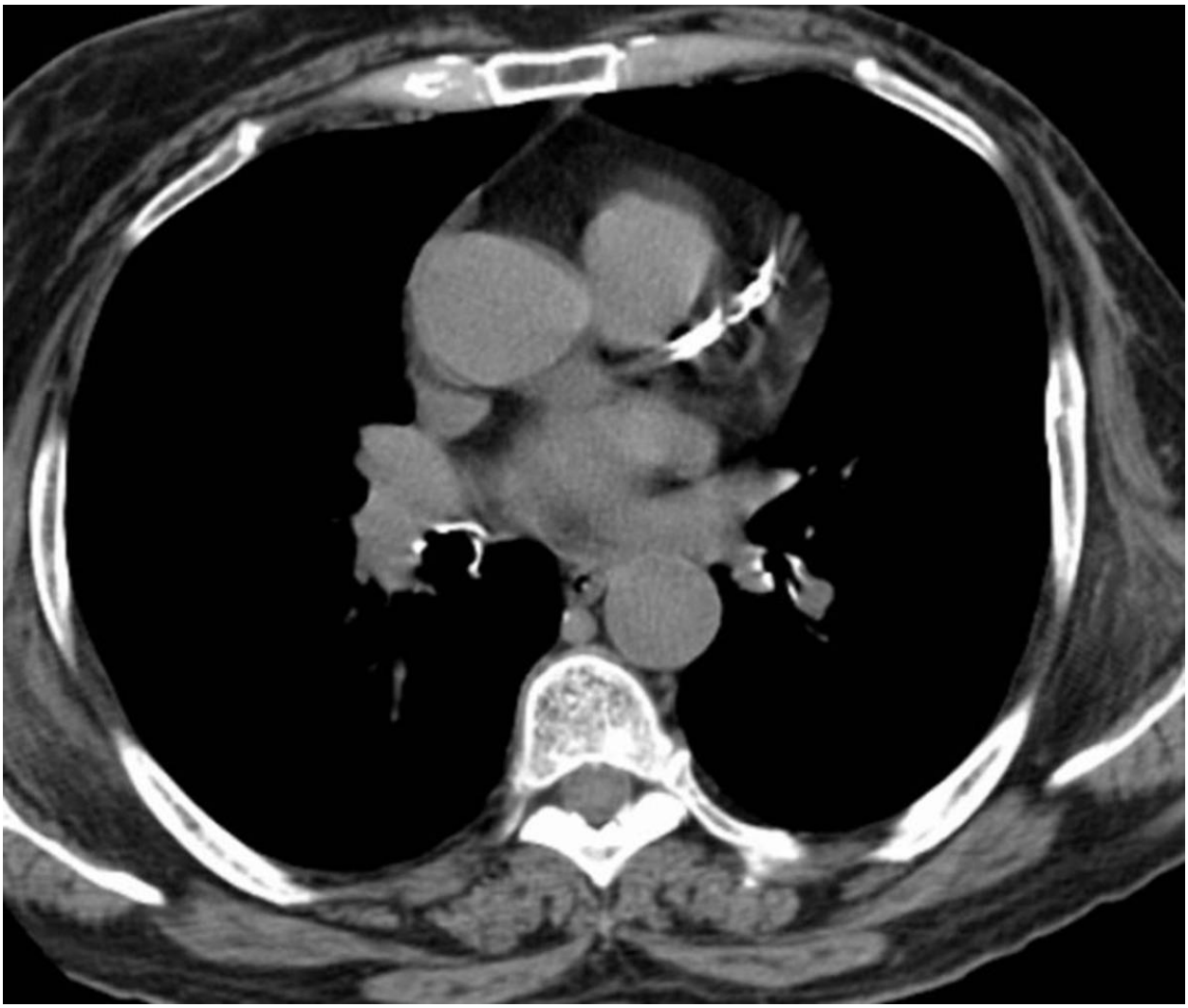

Fig.: Patient with chest pain and renal disease. Axial CT image demonstrates extensive calcification in the distribution of the left anterior descending artery.
References: J. F. Costa; Radiology, Hospitais da Universidade de Coimbra, Coimbra, PORTUGAL

Congenital anomalies related to the coronary arteries are also well demonstrated thanks to the three-dimensional capability of cardiac CT. Anomalies of the coronary artery determined at catheter-based coronary angiography range from 0.3% to 1%, although the prevalence with CT angiography is likely to be higher. Cardiac CT can clearly identify the course of an anomalous coronary artery and demonstrate or exclude the presence of an interarterial course between the ascending aorta and pulmonary artery, which places the individual at higher risk for sudden death.

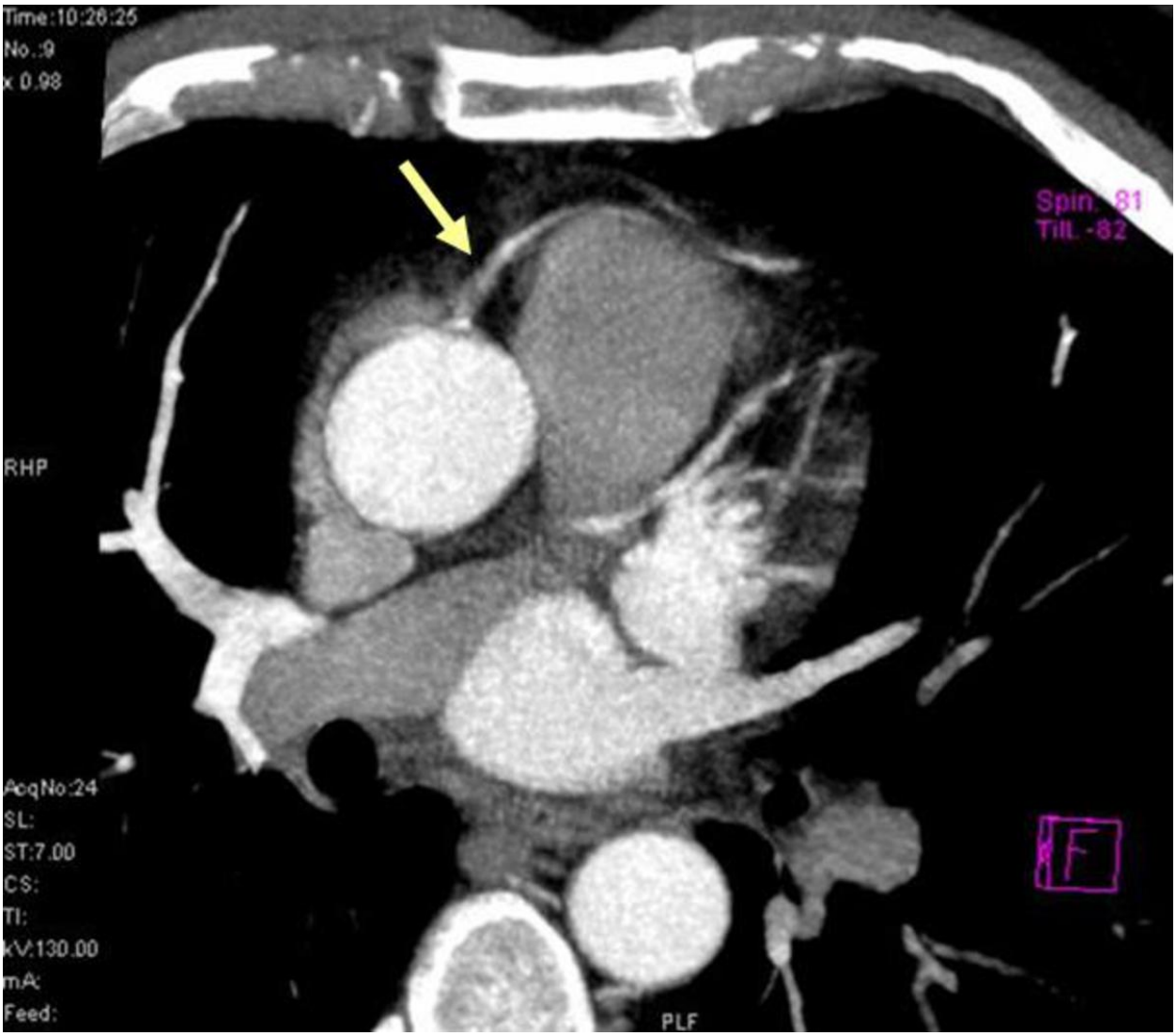

Fig.: Multidetector CT evaluation for syncope and exertional chest pain. MIP image depicts an anomalous position of the right coronary artery (arrow), coursing in front of the main pulmonary artery. Note the normal position of the left main coronary artery and left anterior descending.
References: J. F. Costa; Radiology, Hospitais da Universidade de Coimbra, Coimbra, PORTUGAL

2) <u>Acute aortic syndrome</u>

Acute aortic syndrome describes the subset of aortic emergencies that is characterized by the symptoms of chest pain and hypertension.

These entities include aortic dissection (AD), intramural hematoma (IMH), and penetrating atherosclerotic ulcer. Aortic aneurysm leak and rupture have been included in this categorization.

Aortic dissection

Aortic dissection (AD) usually occurs in the presence of hypertension. The event arises as an intimal tear of the aorta, and blood later dissects into the aortic media to form a false and true lumen.

Tears that develop in the descending aorta (Stanford type B) are managed pharmacologically with antihypertensive therapy. Intimal tears that involve the ascending aorta, whether or not there is extension into the descending aorta (Stanford type A), are associated with a higher mortality that necessitates emergent surgical repair. Surgical management for type B dissections is reserved for complications, such as rapidly expanding aortic diameter, acute or impending aortic rupture, intractable pain, ischemia of limbs and organ systems, and uncontrolled hypertension.

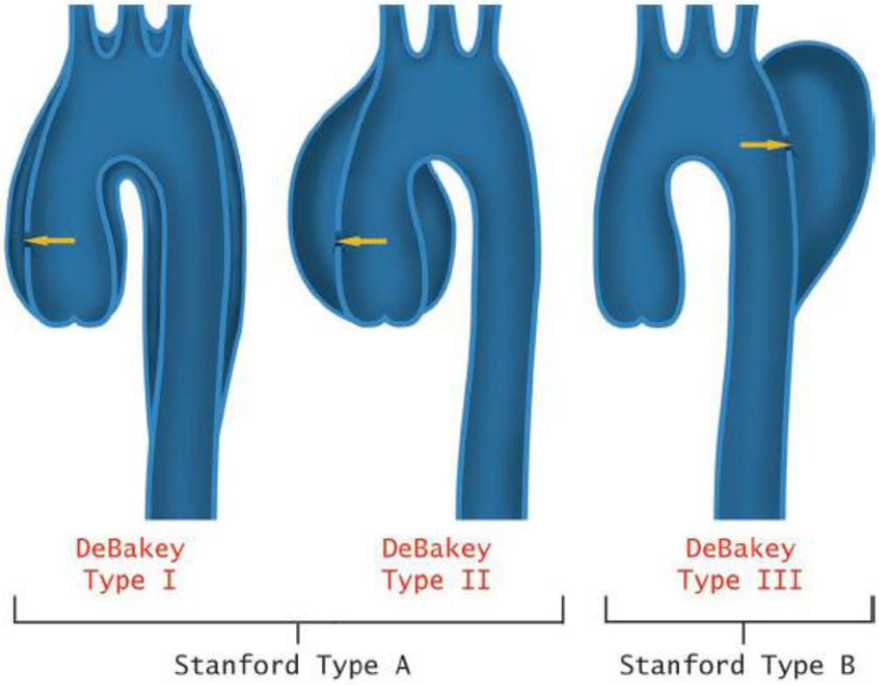

Fig.: Drawing shows the Stanford classifications of aortic dissections and the equivalent DeBakey classifications.
References: Eva Castaner et al (2003); CT in Nontraumatic Acute Thoracic Aortic Disease: Typical and Atypical Features and Complications. RadioGraphics 23:S93-S110

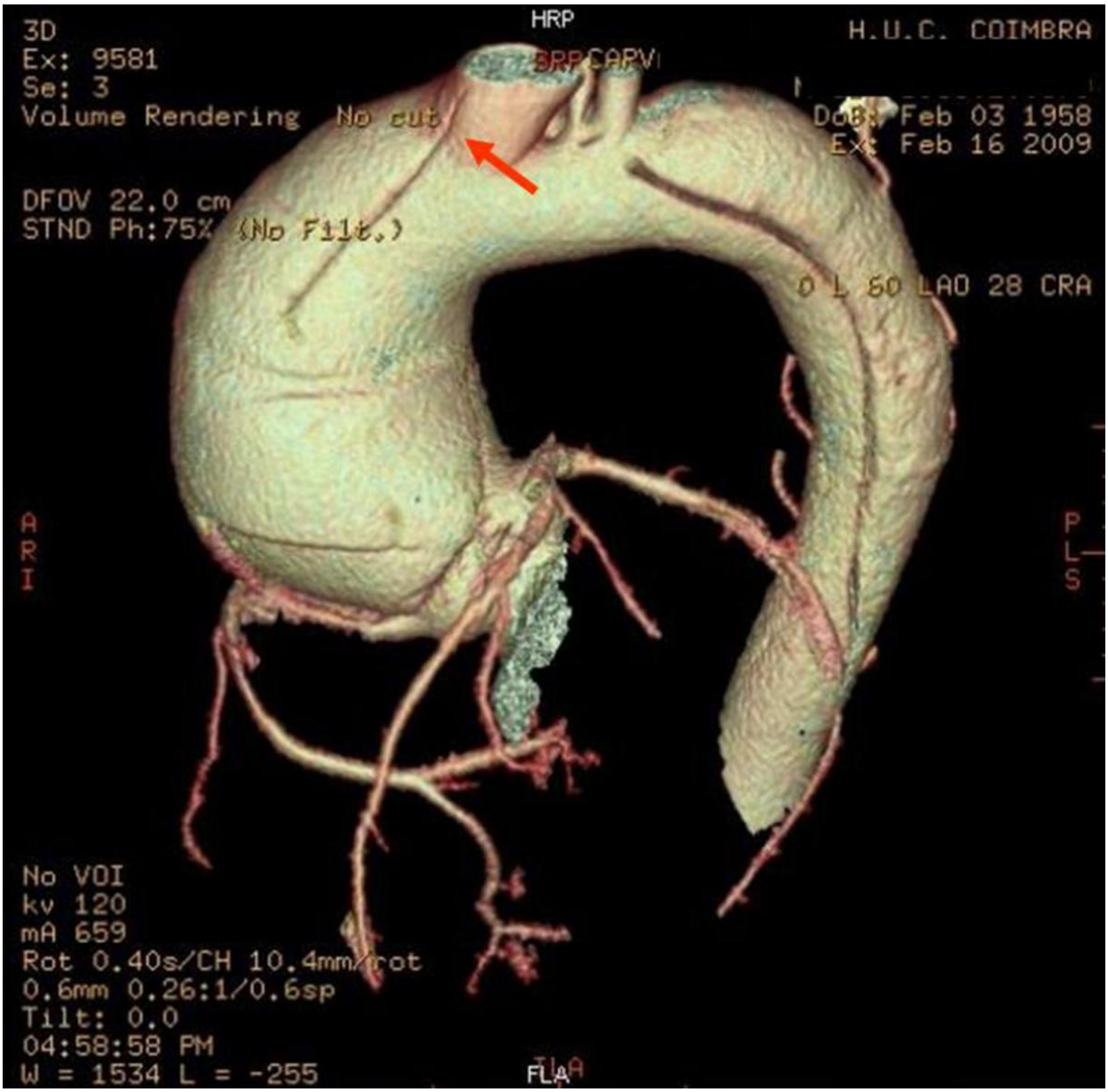

Fig.: Typical aortic dissection with supraaortic trunk involvement. VRT of contrast-enhanced CT scan shows intimal flap (arrow) extending to the innominate trunk.
References: J. F. Costa; Radiology, Hospitais da Universidade de Coimbra, Coimbra, PORTUGAL

In autopsy series, the entrance tear is located in the ascending aorta in 70% of patients, in the aortic arch in 10%, in the descending thoracic aorta in 20%, and rarely within the abdominal aorta. This contrasts with surgical or radiologic studies, in which dissections in the descending aorta are more common, because these studies include the survivors of aortic dissection. In dissections involving the ascending aorta, the entrance tear is typically in the right lateral aortic wall. Re-entrance tears are found less frequently, and in some cases a single tear may be present so that flow within the false channel is bidirectional.

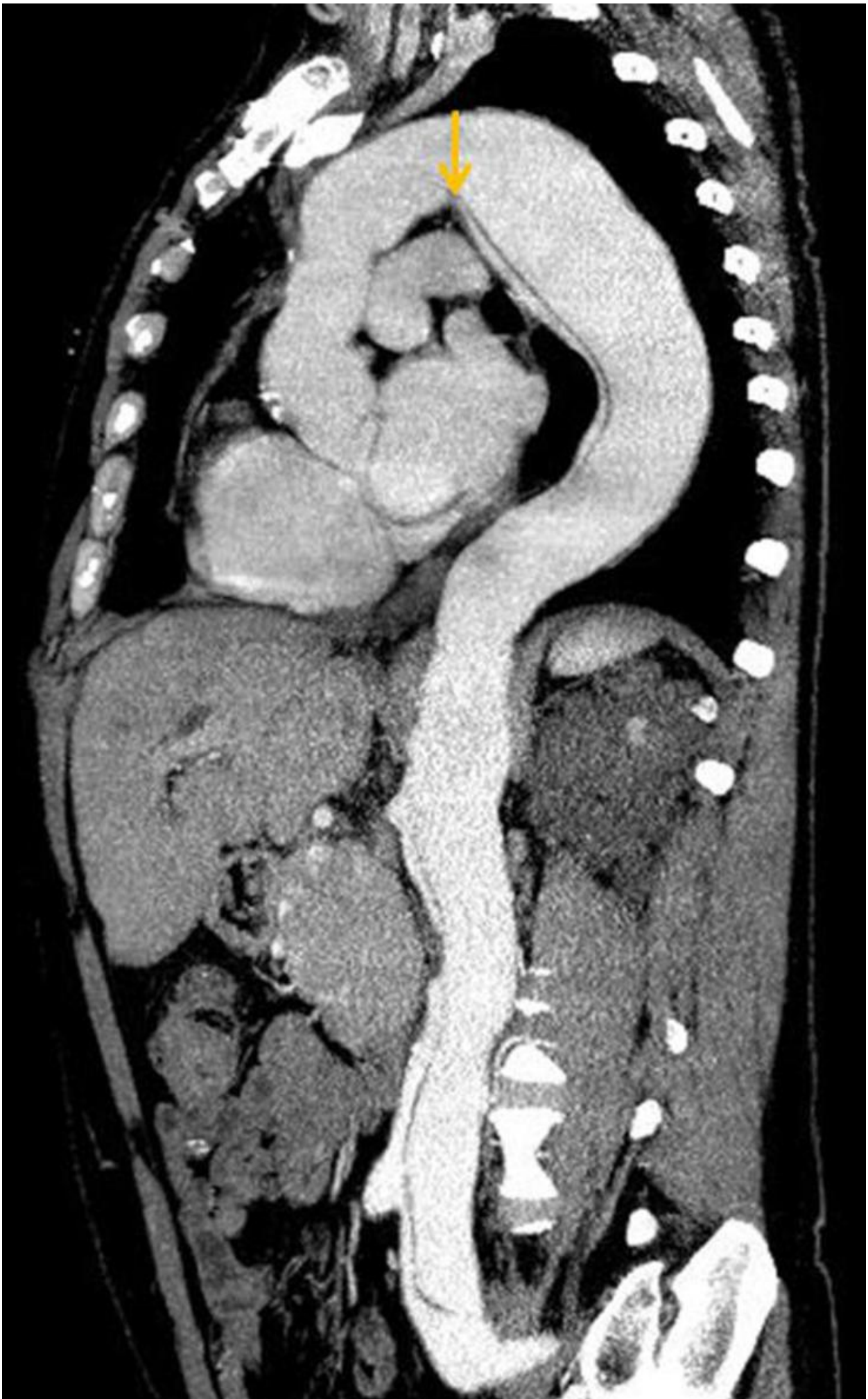

Fig.: Type B aortic dissection. The dissection begins (arrow) distal to the left subclavian artery and extends to both common iliac arteries (only left common iliac is shown).
References: J. F. Costa; Radiology, Hospitais da Universidade de Coimbra, Coimbra, PORTUGAL

Unenhanced CT images provide information that can be obscured by intravenous contrast material. On CT scans performed without intravenous contrast material, displacement of intimal calcification from the aortic wall is consistent with a diagnosis of aortic dissection. This can mimic, however, calcification of mural thrombus within an aortic aneurysm.

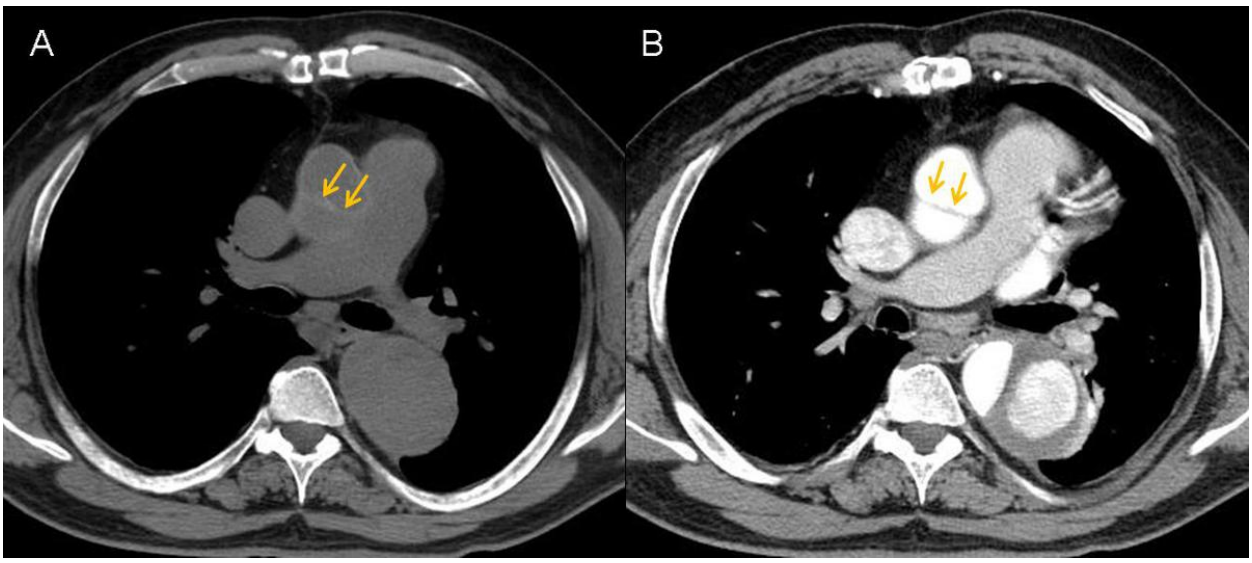

Fig.: Type A aortic dissection. A. Precontrast image. Visible intimal flap (arrows) as linear structure slightly higher in attenuation than surrounding blood. B. After CIV the intimal flap (arrows) is easily seen.
References: J. F. Costa; Radiology, Hospitais da Universidade de Coimbra, Coimbra, PORTUGAL

A major role for unenhanced images is the depiction of intramural hematoma (IMH). In patients who have aortic IMH, a narrow rim of high-attenuation material is present within the aortic wall, either in a crescentic or circumferential pattern. In patients who had aortic rupture, the high attenuation of acute blood is readily apparent within the mediastinum, pericardial sac, or pleural space on unenhanced CT.

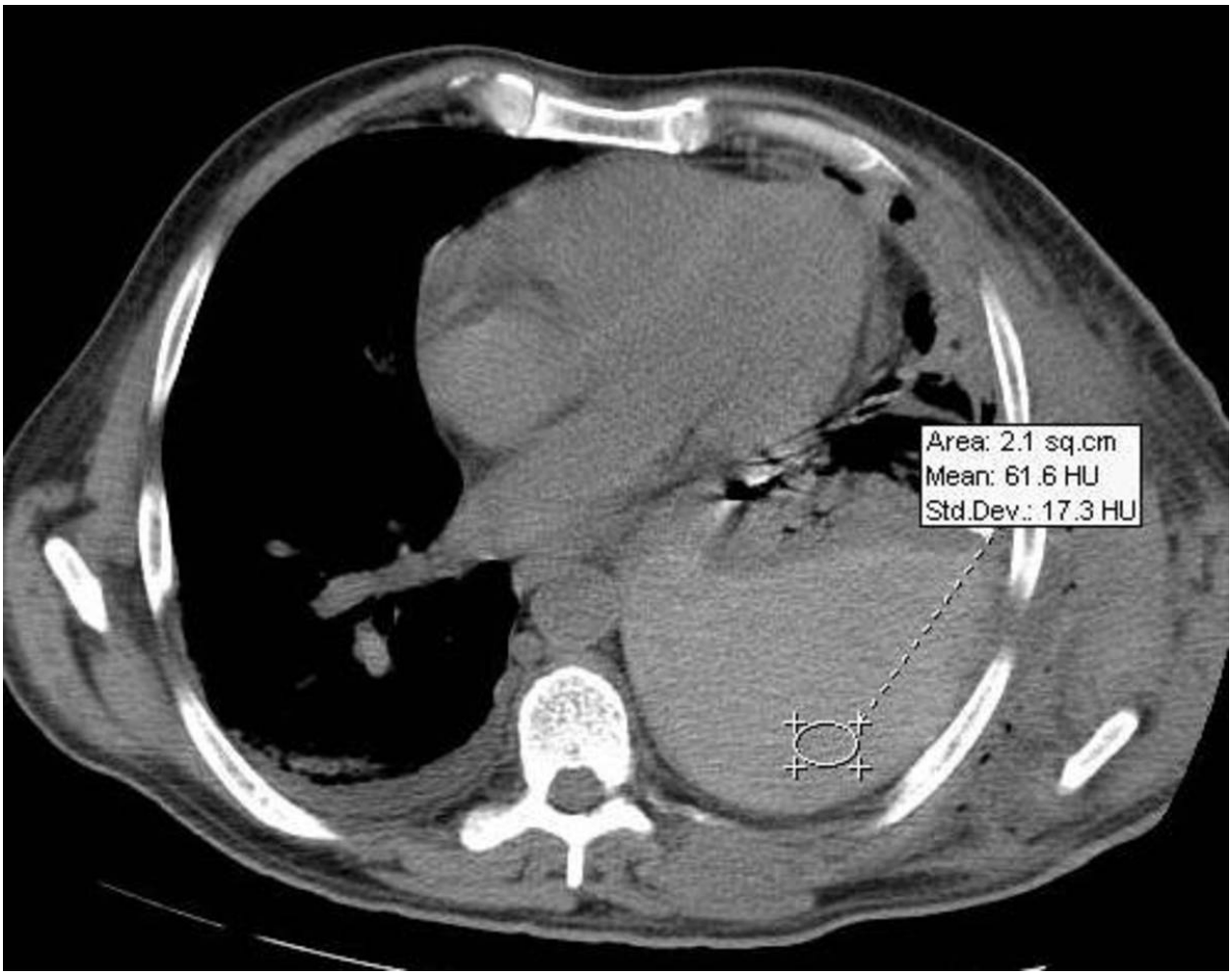

Fig.: Volumous left-sided hemorrhagic pleural effusion (CT attenuation of 62 HU) secondary to rupture of an ascending aorta dissection (not shown). There is also a small pleural effusion on the right side.
References: J. F. Costa; Radiology, Hospitais da Universidade de Coimbra, Coimbra, PORTUGAL

The primary finding on a contrast-enhanced CT is the identification of the intimomedial flap that separates the true and false lumens.

In most cases, the true lumen can be recognized by continuity with an uninvolved portion of the aorta.

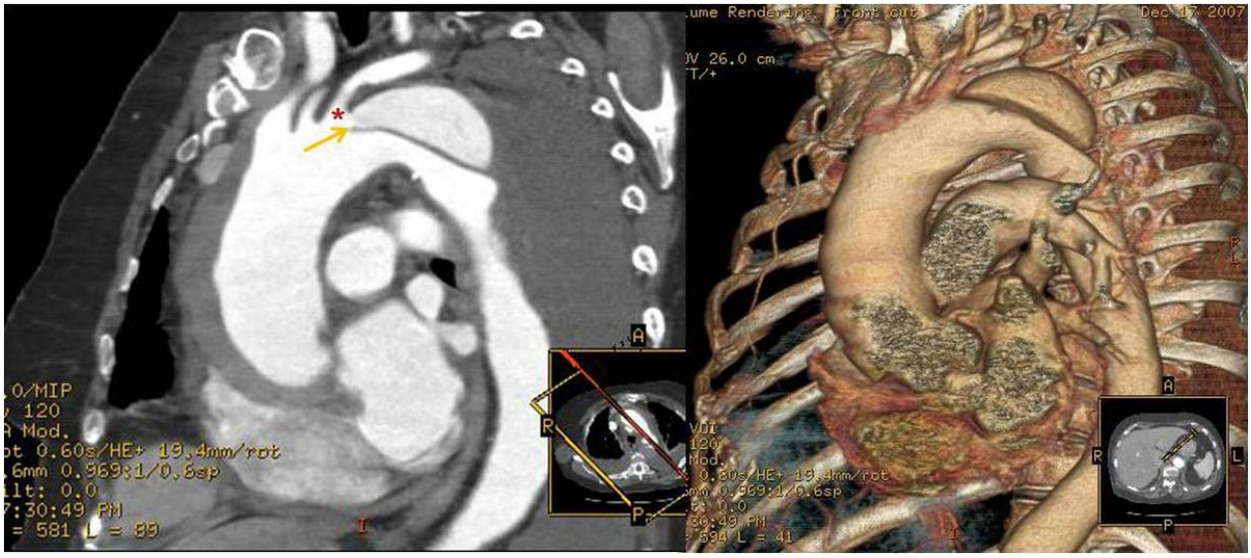

Fig.: Acute dissection that begins distal to the left subclavian artery (asterix) is classified as Stanford type B (DeBakey type III).
References: J. F. Costa; Radiology, Hospitais da Universidade de Coimbra, Coimbra, PORTUGAL

The true lumen is usually small, containing blood flow traveling at a high velocity, compared with slower blood flow in a larger false lumen. On contrast-enhanced CT, these differing rates of blood flow may be apparent as differing rates of contrast enhancement.

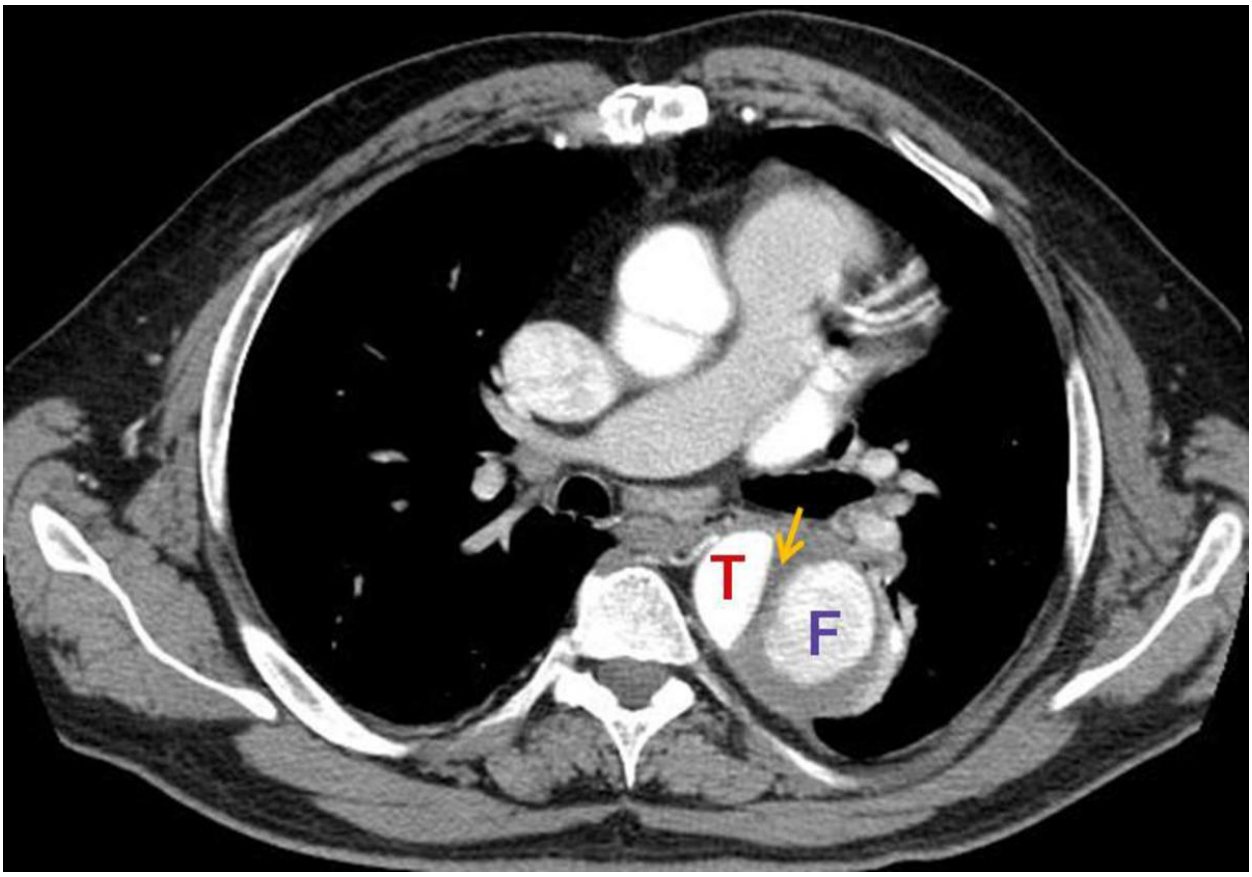

Fig.: Type A aortic dissection. The true lumen (T) is usually small, containing blood flow traveling at a high velocity, compared with slower blood flow in a larger false lumen (F). On this contrast-enhanced CT, the differing rates of blood flow are apparent as differing rates of contrast enhancement.
References: J. F. Costa; Radiology, Hospitais da Universidade de Coimbra, Coimbra, PORTUGAL

On cross-sectional imaging, the junction of the intimal flap and the outer wall of the false lumen form an acute angle, created as the sharp wedge of the hematoma cleave the aortic media. On CT, this has been called the "beak sign".

Another indicator of the false lumen is the presence of aortic cobwebs. Aortic cobwebs most likely represent strands of fibrous tissue that have been incompletely sheared from the aortic walls during the dissection, and are a hallmark of the false lumen. On CT, cobwebs are thin filling defects, attached at one end to the aortic wall, within the contrast-filled false lumen.

Atherosclerotic calcification in the outer wall of an aortic lumen indicates the true lumen of an acute aortic dissection, and may appear continuous with the calcified intimal flap representing the inner wall of the false lumen. In chronic dissection, the outer wall of the false lumen may endothelialize and calcify, so that this sign may not be valid.

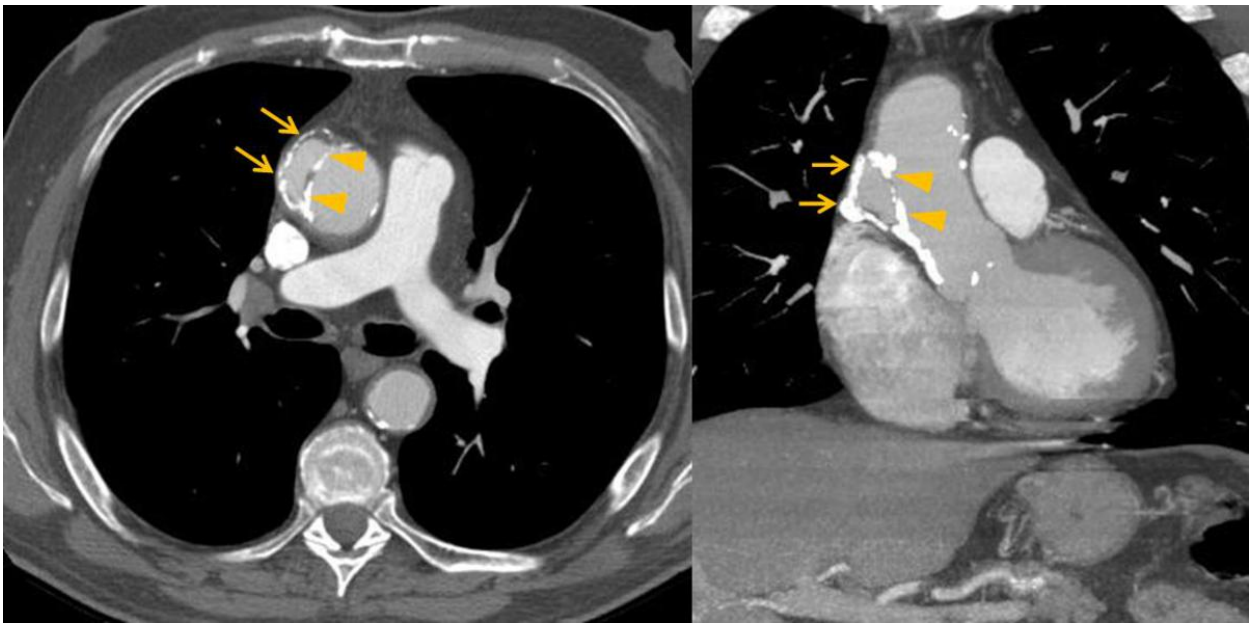

Fig.: Chronic dissection. This patient had acute chest pain, however CT demonstrated wall calcifications in the false channel (arrows; arrowheads: intima) indicative of a chronic process and aortic dissection could be excluded as the cause of acute chest pain.
References: J. F. Costa; Radiology, Hospitais da Universidade de Coimbra, Coimbra, PORTUGAL

In select patients, such as those who have contrast allergy, MR imaging can provide quality images of the entire aorta, showing extent of the dissection, site of the tear, involvement of branch vessels, and involvement of the aortic valve (with functional information regarding valvular insufficiency). However, MR imaging is expensive, time consuming and not widely available and limits access to the potentially unstable patient.

Fig.: MR angiography demonstrate aneurysmal dilatation of the aorta as well as an intimomedial flap (arrow) that are compatible with a type A dissection.
References: J. F. Costa; Radiology, Hospitais da Universidade de Coimbra, Coimbra, PORTUGAL

Intramural hematoma

IMH represents a clinically indistinguishable variant of AD in which no discrete intimal flap is identified, and no flowing blood is observed within the false channel. Spontaneous hemorrhage of the vasa vasorum weakens the media without an intimal tear. The resultant hemorrhage can extend longitudinally along the aorta and may progress to frank dissection.

The primary finding of IMH on noncontrast CT is a crescentic region of increased attenuation, which represents a hematoma in an intramural location. The potential for this finding to be occult and overlooked on contrast enhanced CT imaging necessitates the addition of a noncontrast study when an acute aortic syndrome is suggested.

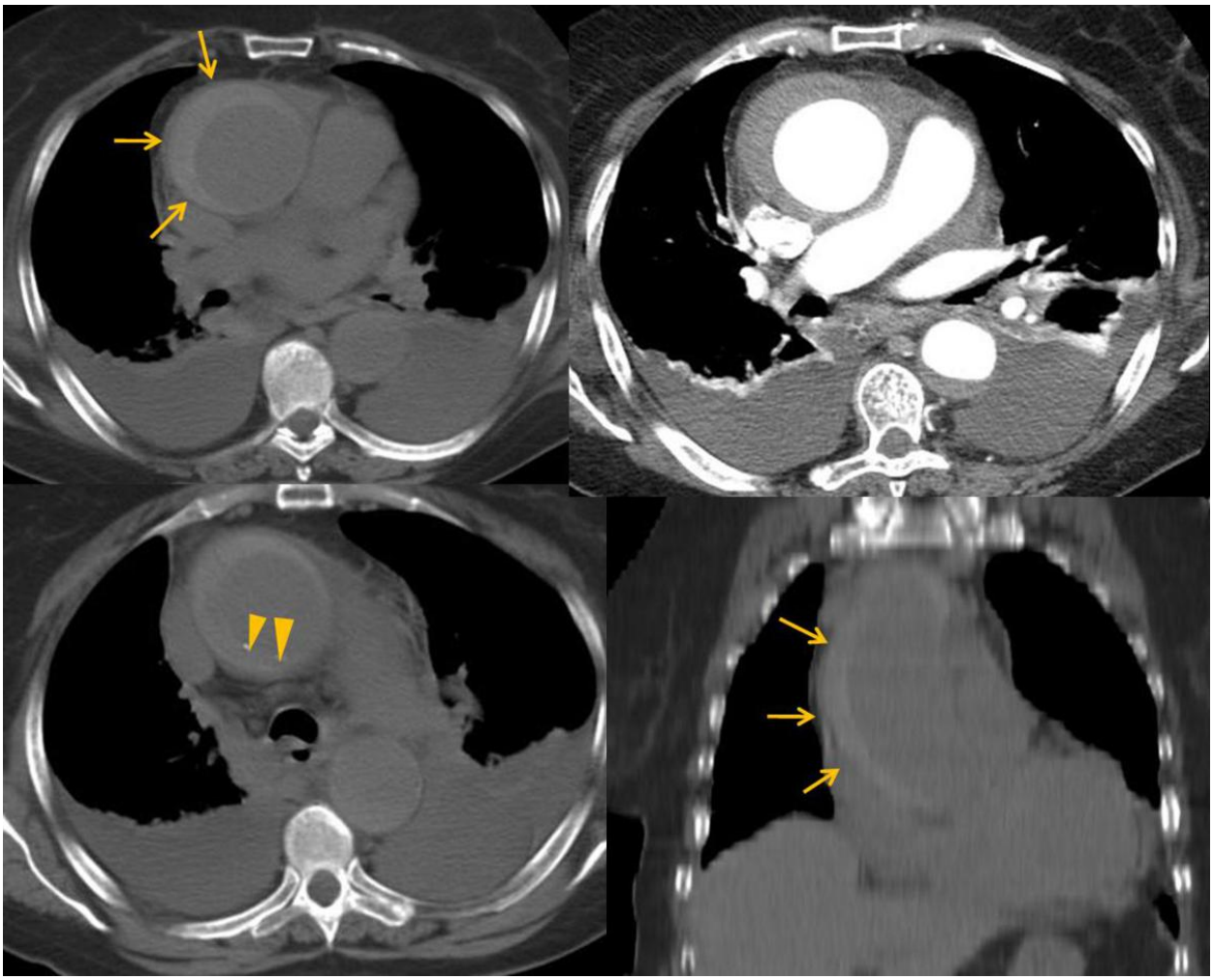

Fig.: Intramural hematoma, type A distribution. Non-contrast enhanced CT demonstrates a hyperdense crescentic area in the lateral and anterior wall of the ascending aorta (arrows), with concomitant displacement of intimal calcifications (arrowheads). Intramural hematoma is harder to appreciate after contrast material injection (endoluminal thrombus can also have this appearance).
References: J. F. Costa; Radiology, Hospitais da Universidade de Coimbra, Coimbra, PORTUGAL

Additional findings include displacement of intimal calcifications, lack of intramural enhancement excluding free flow from classic acute dissection, and compression of the true aortic lumen by the hematoma. One series showed the distribution of all IMHs to be 48% in the ascending aortic, 8% in the aortic arch, and 44% in the descending aorta.

Differentiation of IMH from intraluminal thrombus on a contrast-enhanced CT may be difficult. Features that suggest IMH are displaced intimal calcifications, and a crescentic or circumferential distribution of the now (relative to contrast) low attenuating material. Intraluminal thrombus is often localized, and within a dilated aorta, whereas IMH may extend over a longer distance, within a nondilated aorta.

Type A IMH is more likely to progress to dissection if the initial CT demonstrates an aortic diameter of more than 5 cm. Current therapy for IMH parallels that for aortic dissection; early surgical repair or endovascular placement of a stent-graft is considered for patients who have IMH involving the ascending aorta. Patients who have IMH involving only the descending aorta are managed medically, with aggressive antihypertensive treatment and frequent follow-up imaging examinations.

Penetrating ulcer

Penetrating atherosclerotic ulcer most commonly involves the middle or distal third of the descending thoracic aorta, although any part of the aorta may be involved.

A calcified atheromatous plaque, easily identified on unenhanced CT images, ulcerates and disrupts the internal elastic lamina and then penetrates the underlying intimal and medial layers. A contrast-filled outpouching often extends beyond the plaque and wall of the aortic lumen. The resultant hemorrhage in the media leads to IMH. Thickening and enhancement of the involved aortic wall also can be seen.

Additional complications include focal dissection, disruption of the adventitia that leads to pseudoaneurysm, or aortic rupture.

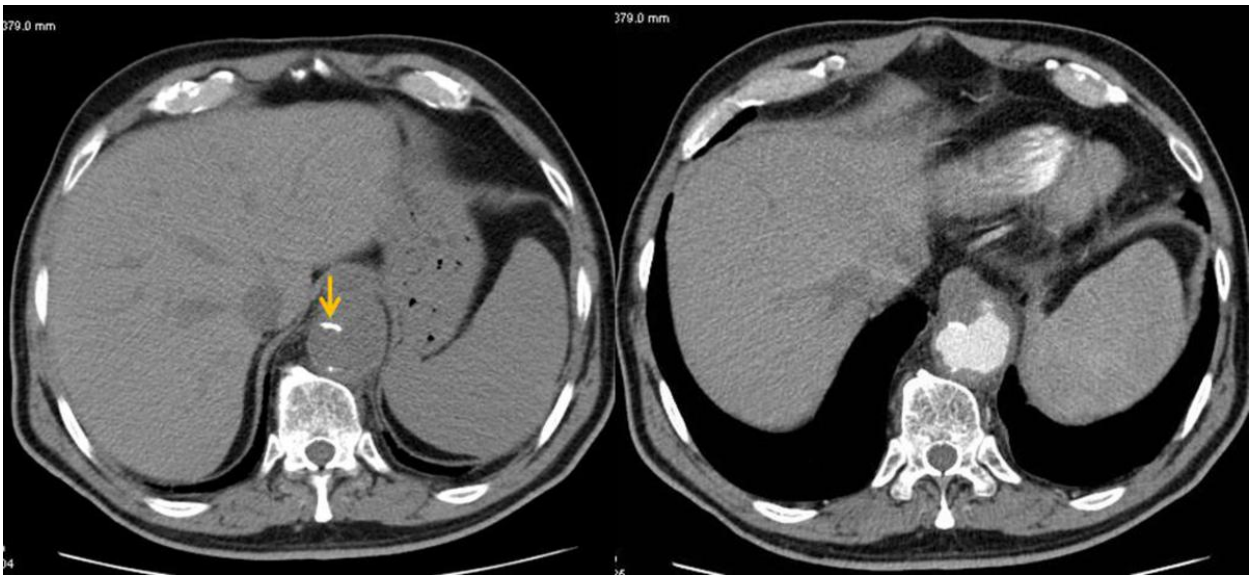

Fig.: Penetrating atherosclerotic ulcer. CT shows a pseudo-aneurysm of the left antero-lateral aspect of the distal descending thoracic aorta and intima calcification (arrows).
References: J. F. Costa; Radiology, Hospitais da Universidade de Coimbra, Coimbra, PORTUGAL

Endovascular stent placement has become a widely accepted method of treatment in these patients.

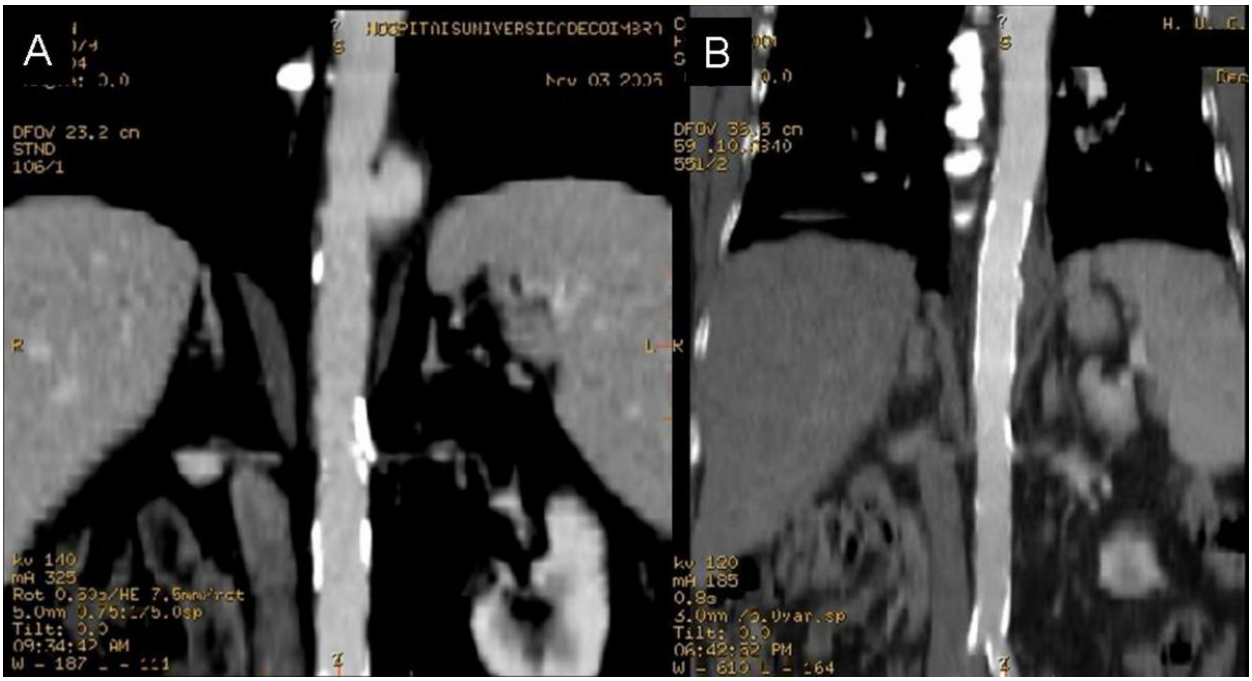

Fig.: Penetrating atherosclerotic ulcer. Saccular aneurysm before (A) and after (B) stenting.

References: J. F. Costa; Radiology, Hospitais da Universidade de Coimbra, Coimbra, PORTUGAL

Aortic aneurysm

A true aortic aneurysm involves all three layers of the aortic wall and most commonly is due to atherosclerosis. False aortic aneurysms (pseudoaneurysms) often are the result of trauma to the intimal wall and containment of the resultant hemorrhage by the outer layers of media or adventitia.

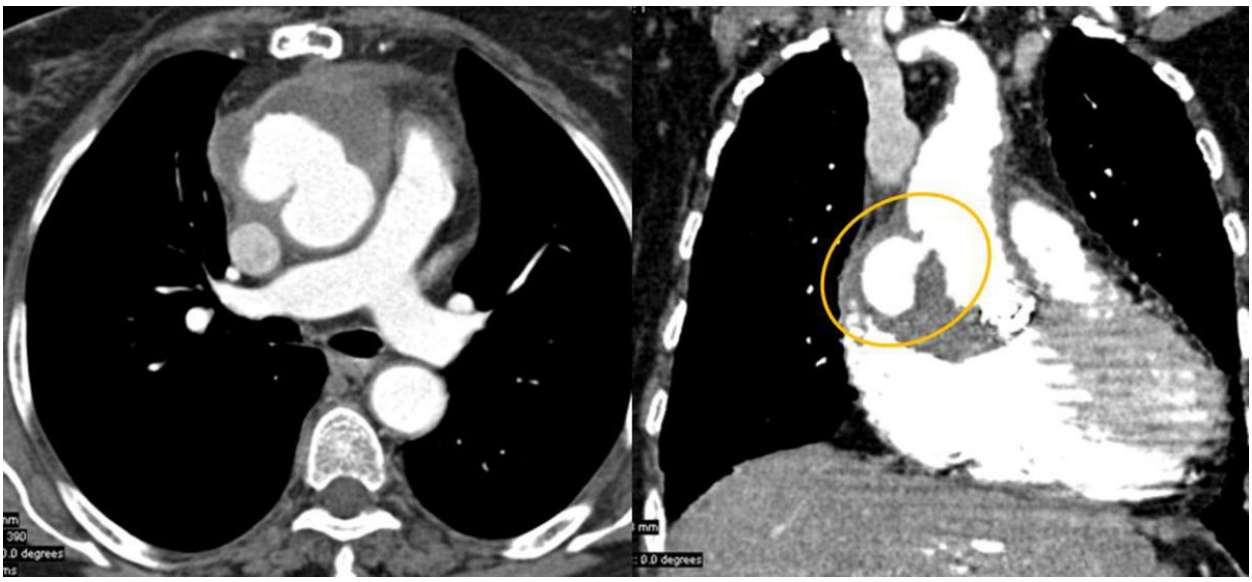

Fig.: Contained rupture of ascending aorta characterized by acute pseudo-aneurysm formation (circle).
References: J. F. Costa; Radiology, Hospitais da Universidade de Coimbra, Coimbra, PORTUGAL

Although many aortic aneurysms are asymptomatic, approximately one third of patients who are diagnosed with an intact TAA experience an aortic rupture within a month of diagnosis. Other patients who are at risk present with pain that is related to mass effect or enlarging size.

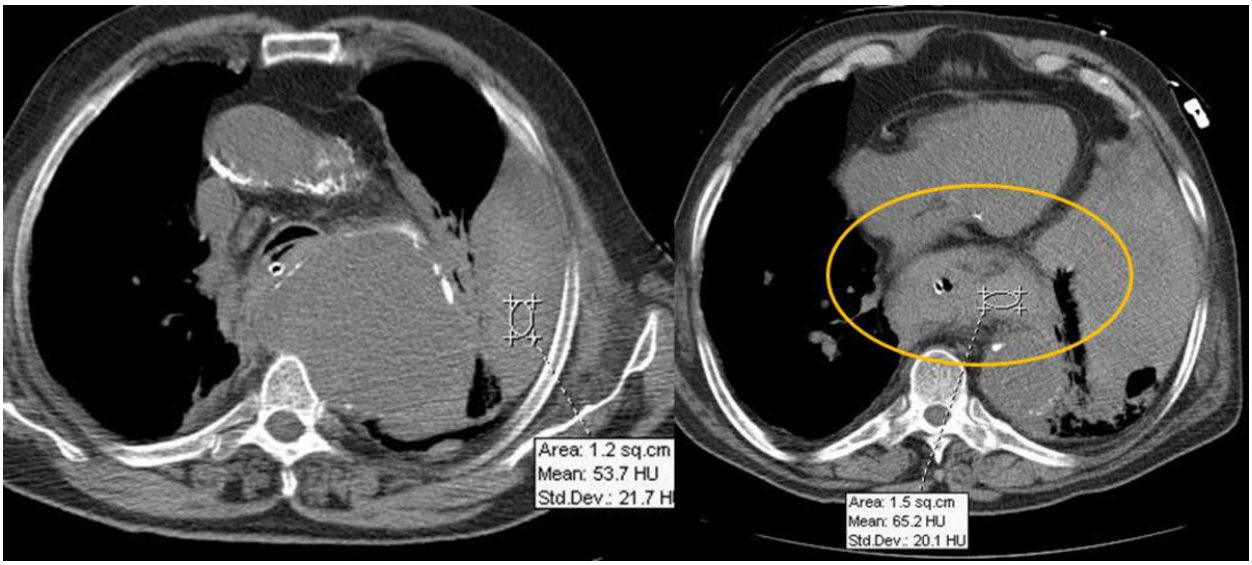

Fig.: Ruptured descending aorta aneurysm. There is a large left hemothorax (HU > to 50) and hematoma in posterior mediastinum (circle).
References: J. F. Costa; Radiology, Hospitais da Universidade de Coimbra, Coimbra, PORTUGAL

CT imaging, with sensitivity and specificity that is comparable to conventional aortography, offers the best evaluation because it is noninvasive, readily available in most EDs, and allows for detailed assessment of the aorta with three dimensional reconstruction techniques.

Infectious vascular process (***mycotic aneurysm***) describes aneurysms that result from bacteremia and embolization of any infectious material, with superinfection of an atheromatous plaque. Alternatively, direct extension from an extravascular infectious focus, such as vertebral osteomyelitis, may penetrate into an adjacent vascular structure and lead to necrosis, bleeding, and pseudoaneurysm formation. Characteristic findings include a periaortic soft tissue mass, stranding, and fluid.

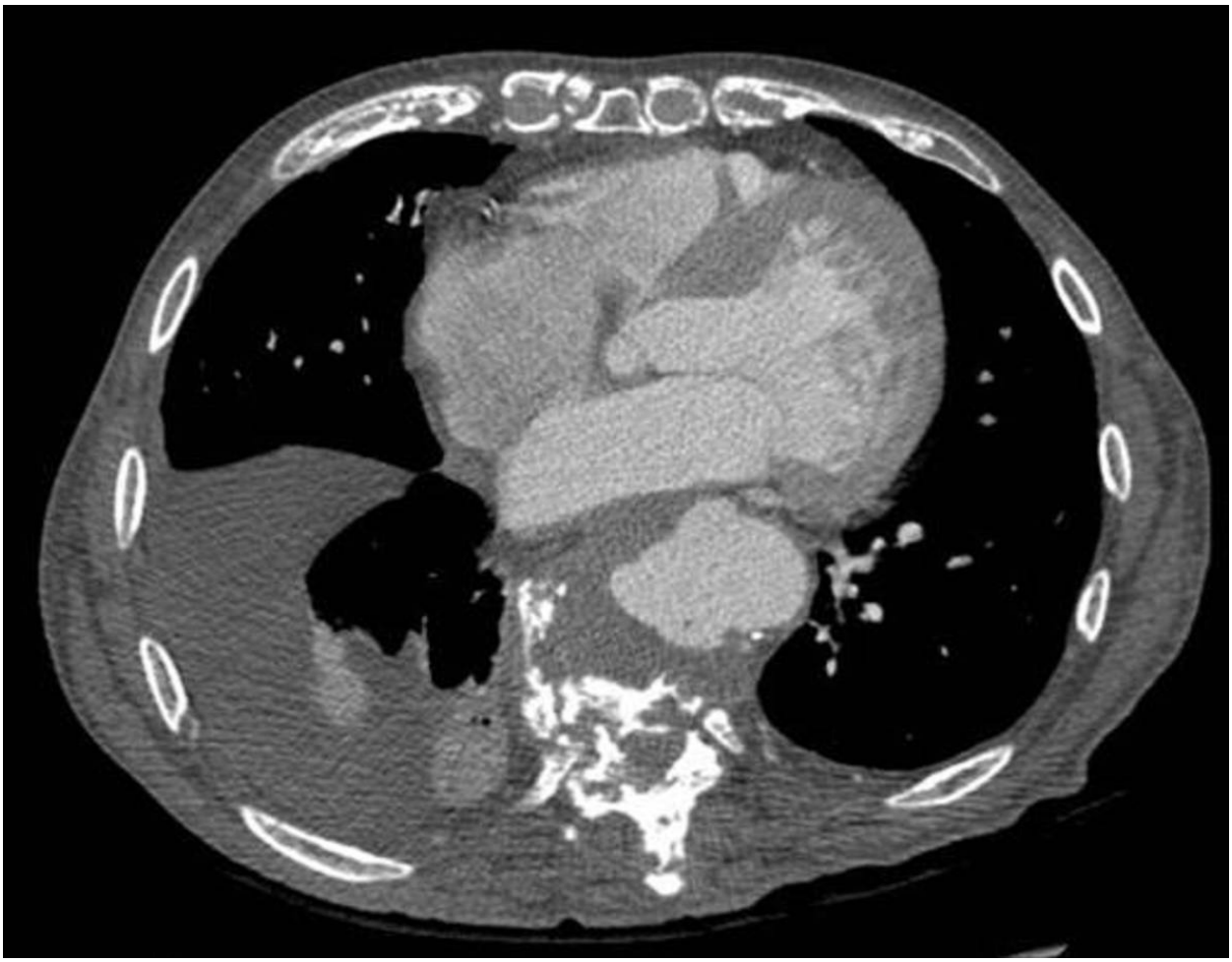

Fig.: Contrast-enhanced axial CT image demonstrates a pseudoaneurysm of the aorta with extensive surrounding infiltrative changes, secondary to vertebral osteomyelitis. There is extensive destruction of adjacent vertebral body. A right pleural effusion is also present.
References: J. F. Costa; Radiology, Hospitais da Universidade de Coimbra, Coimbra, PORTUGAL

Spontaneous aortic rupture

Rupture of the aorta often is the fatal natural history of any aortic syndrome.

Periaortic hematoma is one of the hallmark findings. Another sign of impending rupture is hyperdense mediastinal, pericardial, or pleural fluid that is compatible with hemorrhage on unenhanced CT of the chest.

The presence of IMH, focal defect in a calcified aortic wall, and extravasation of contrast material also are ominous signs on a contrast-enhanced study.

3) Pulmonary embolism

PE must be considered in every patient who has chest pain and dyspnea. Only 30% of PE are diagnosed before death. Alternatively, less than 35% of patients who are suspected of having a PE actually have one. The classic presentation of PE is chest pain, dyspnea, and hemoptysis; however, this triad is present in less than 20% of patients.

Chest radiography often is abnormal, but nonspecific, and may elucidate other diagnoses. The classic signs of relative oligemia (Westermark's sign) and wedge-shaped pulmonary opacity (Hampton's hump) are rare. It is helpful in the diagnosis of diseases that may mimic PE clinically, such as pneumonia. It is also helpful in the interpretation of ventilation perfusion scintigraphy.

Multidetector CT angiography is becoming the initial study of choice in the acute setting for the diagnosis of PE, primarily because of its widespread availability, speed, and noninvasive nature.

The primary imaging feature of PE is identification of an intraluminal full or partial pulmonary arterial filling defect.

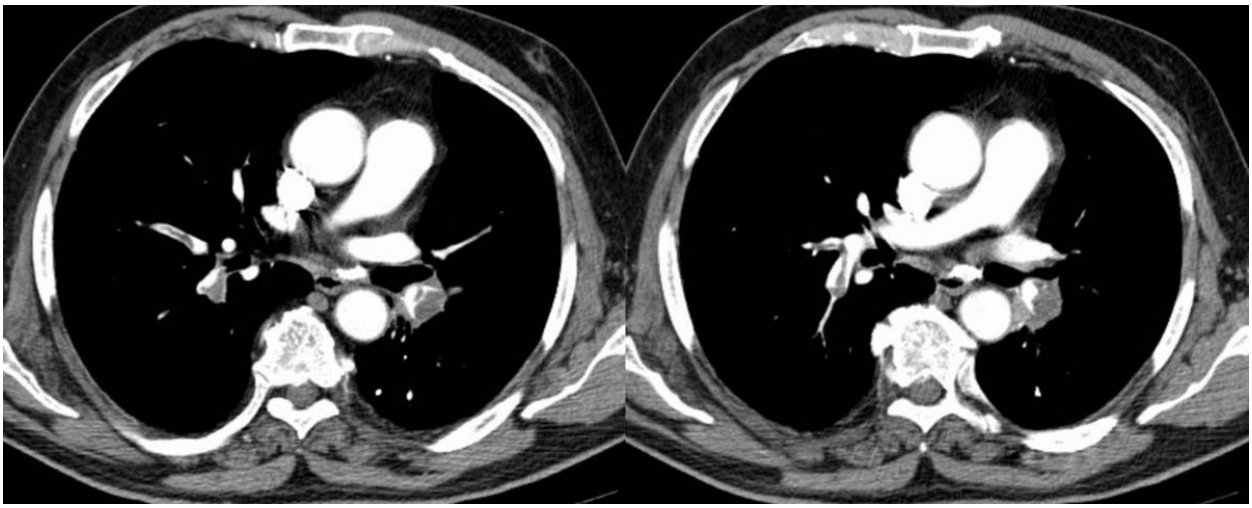

Fig.: Bilateral pulmonary embolism. Clot is visualized directly in the left lower lobe pulmonary artery and segmental arteries of the lower right lobe.
References: J. F. Costa; Radiology, Hospitais da Universidade de Coimbra, Coimbra, PORTUGAL

The thrombi typically originate in the deep veins of the lower extremities, and the long, narrow thrombi straddle the bifurcations of the pulmonary arteries. The largest ones, straddling the bifurcation of the main pulmonary arteries, are called "saddle emboli," but

this same phenomenon also occurs throughout the smaller arteries. The embolus may appear somewhat eccentrically located at the level of the bifurcation, with the two limbs floating in the lumen of the downstream vessels. The emboli are typically nonocclusive, although complete vessel cutoff may also be seen when the thromboembolus occludes the vessel. When an artery is imaged longitudinally, contrast may be seen coursing along the margins of the filling defect, producing a "railway track" appearance.

Massive PE may cause acute right ventricular dysfunction and reduced cardiac output. Right ventricular dilatation may be visible on CT, with displacement of the interventricular septum toward the left ventricle. Reid and Murchison suggest that a ratio of right ventricle:left ventricle short-axis diameter of 1.5:1 or greater indicates severe right ventricular strain.

Fig.: Right ventricular dilatation is visible on CT. A ratio of RV:LV short-axis diameter of 1,5:1 or greater indicates severe right ventricular strain.
References: J. F. Costa; Radiology, Hospitais da Universidade de Coimbra, Coimbra, PORTUGAL

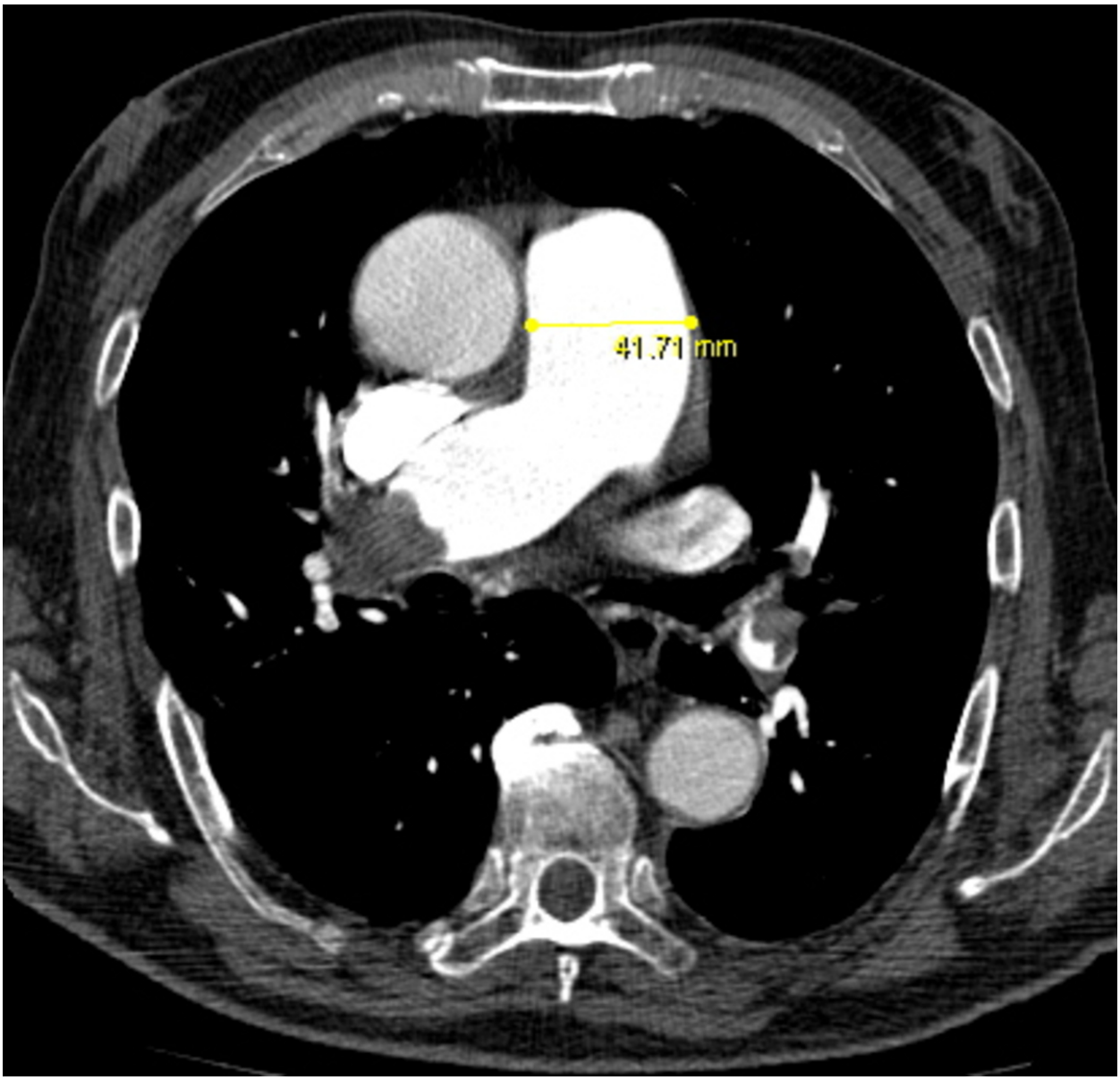

Fig.: Pulmonary arterial hypertension secondary to acute pulmonary embolism. On a CT scan, the pulmonary artery measures 42 mm in diameter (yellow line), a finding that indicates hypertension. Thromboemboli are visible bilaterally as filling defects in the right pulmonary artery, and in the left descending pulmonary artery.
References: J. F. Costa; Radiology, Hospitais da Universidade de Coimbra, Coimbra, PORTUGAL

Reflux of contrast material into the inferior vena cava may also be encountered.

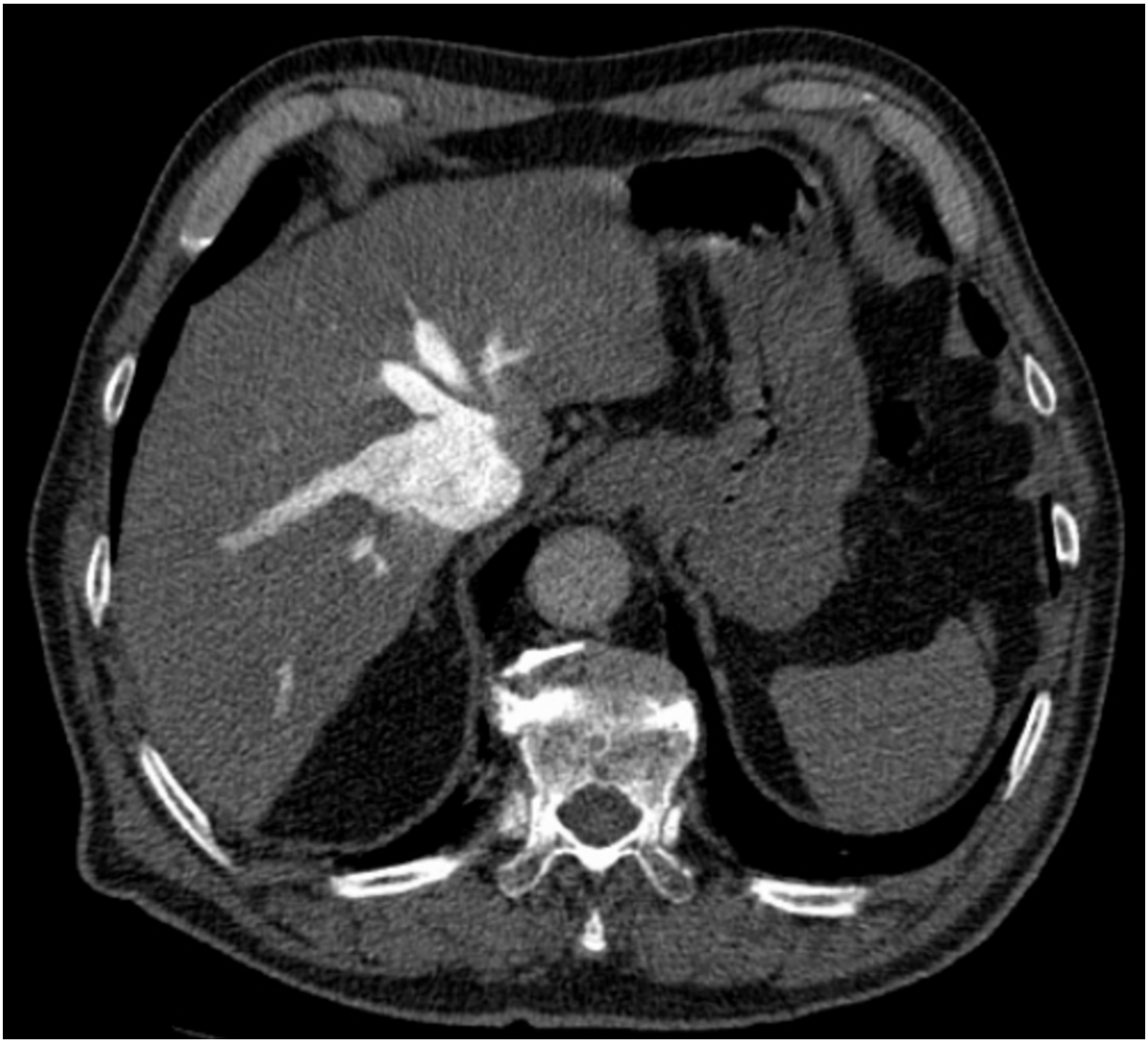

Fig.: Reflux of contrast medium into the hepatic veins and IVC is an indirect sign of tricuspid valve insufficiency, frequently observed in right heart failure. During severe acute PE, tricuspid regurgitation may develop as a result of RV dilatation, further reducing RV output.
References: J. F. Costa; Radiology, Hospitais da Universidade de Coimbra, Coimbra, PORTUGAL

On lung window settings, pulmonary parenchymal abnormalities may also be seen in pe patients. These abnormalities include pleural-based, wedge-shaped consolidation; oligemia; and pleural effusion.

Fig.: Pulmonary infarction in a patient with pulmonary embolism. a) and b) A wedge-shaped opacity is visible in the peripheral lung, contacting the pleural surface and associated with surrounding ground-glass opacity (halo sign), consistent with adjacent hemorrhage. c) angio-TC shows a pulmonary embolus in the lateral segmentar artery of the medium lobe (arrow).
References: J. F. Costa; Radiology, Hospitais da Universidade de Coimbra, Coimbra, PORTUGAL

Fig.: Pulmonary infarction in a patient with pulmonary embolism. Wedge-shaped opacity in the periphery of right lower lobe, contacting the pleural surface. A vessel

is noted at the apex of opacity, its feeding vessel. A small reactive pleural effusion is associated.
References: J. F. Costa; Radiology, Hospitais da Universidade de Coimbra, Coimbra, PORTUGAL

Subsegmental emboli and horizontal vessels are not well visualized on CT. Other drawbacks of CT imaging include the use of nephrotoxic contrast and radiation exposure; in addition, the study requires a cooperative patient, because motion artefact limits the quality of the images.

Venous ultrasound and CT venography

Because DVT and PE are both manifestations of a single disorder, venous thromboembolism, which uniformly requires anticoagulation, combined CTPA and venography has been recommended as an imaging technique capable of identifying both PE and DVT.

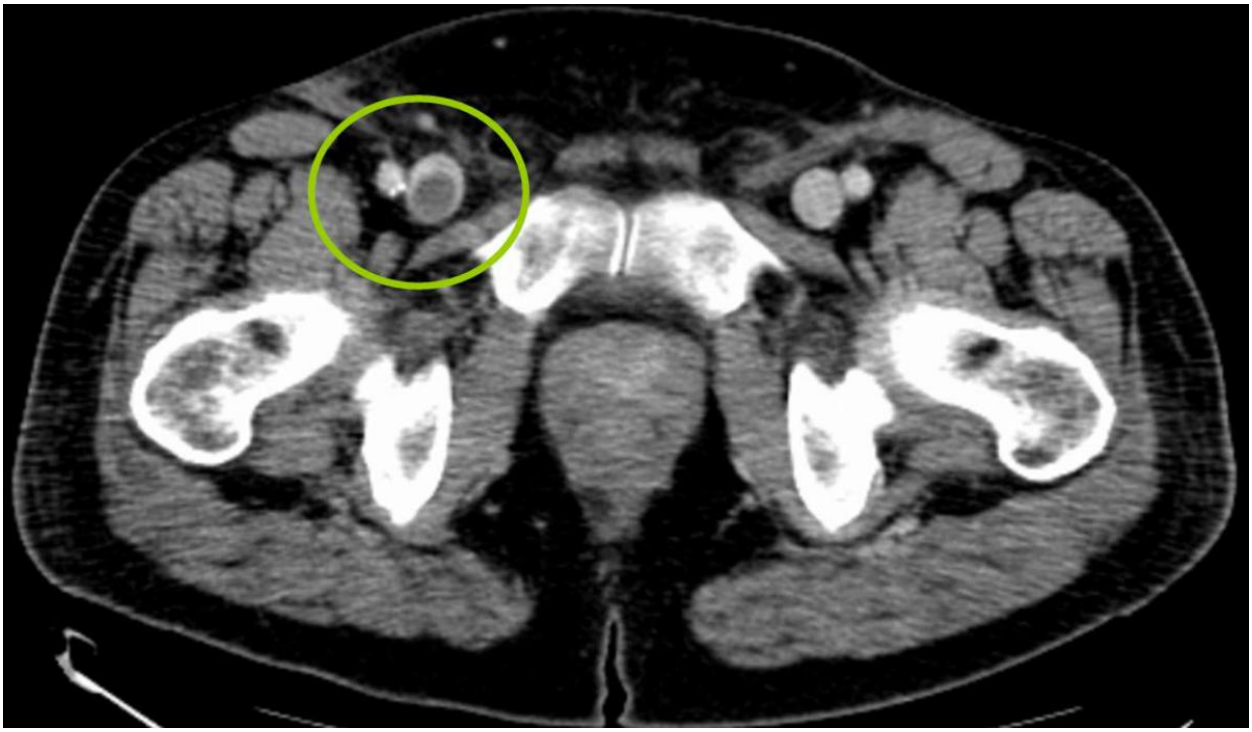

Fig.: Axial image of CT venography reveals pelvic venous thrombosis in the right common femoral vein (circle).
References: J. F. Costa; Radiology, Hospitais da Universidade de Coimbra, Coimbra, PORTUGAL

Currently, compression venous ultrasonography is the procedure of choice in patients who have suspected DVT because of its noninvasive nature, portability, wide availability, and low cost.

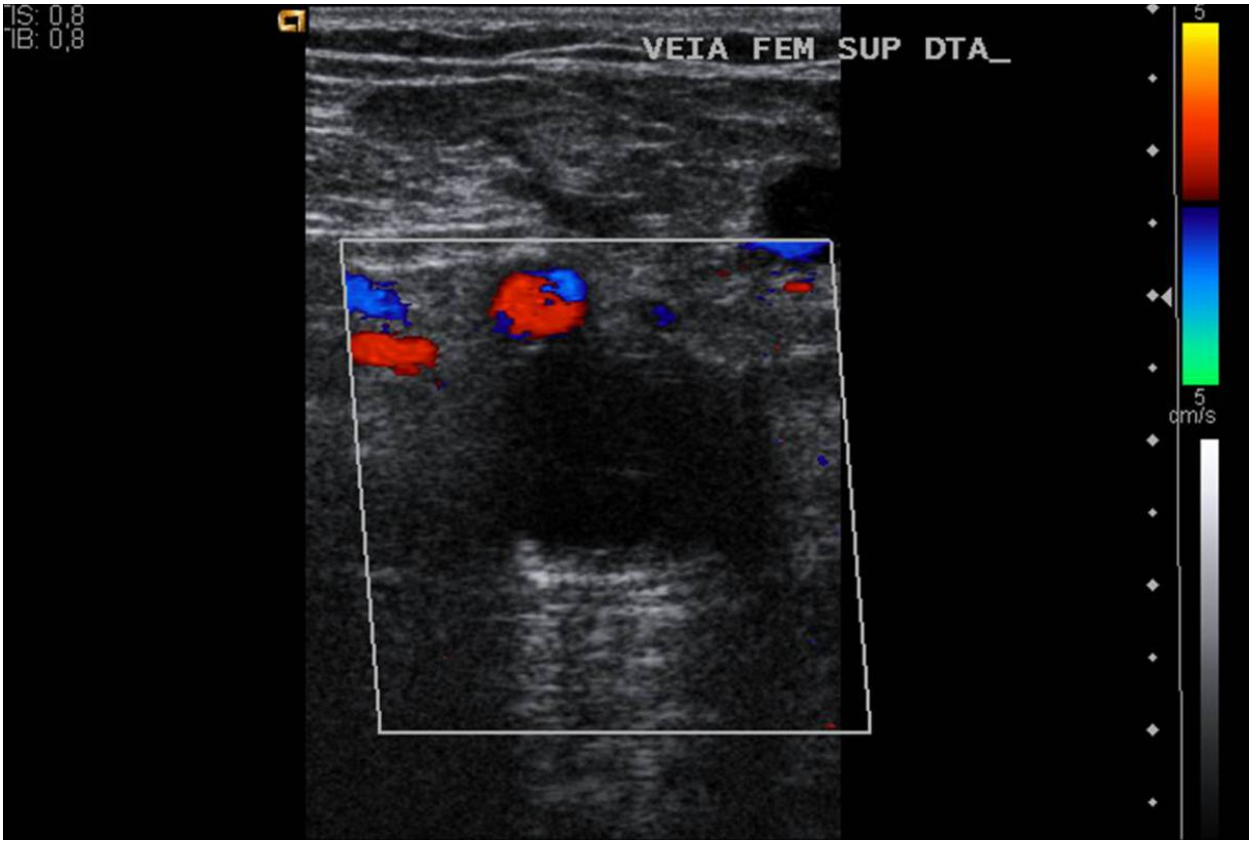

Fig.: Compression venous ultrasonography shows deep venous thrombosis of the superficial femoral vein.
References: J. F. Costa; Radiology, Hospitais da Universidade de Coimbra, Coimbra, PORTUGAL

CT venography has been shown to correlate well with lower-extremity venous sonography, but has the advantage of depicting the iliac veins and inferior vena cava.

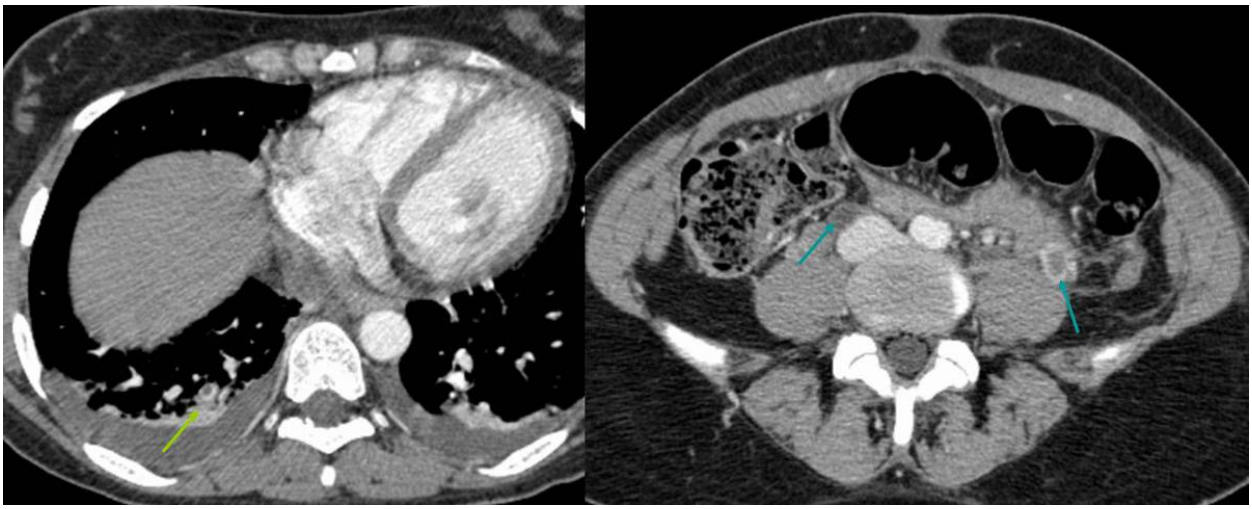

Fig.: Puerperal patient with acute chest pain. A non-occlusive thrombus is identified in a sub-segmental artery of the right lower lobe, in addition to bilateral pleural effusions. There is also bilateral venous thrombosis of the ovarian veins. The evaluation of deeper veins is a significant advantage of CT venography over ultrasonography.
References: J. F. Costa; Radiology, Hospitais da Universidade de Coimbra, Coimbra, PORTUGAL

4) <u>Pneumothorax</u>

Pneumothorax commonly is divided into two types: primary spontaneous pneumothorax and secondary spontaneous pneumothorax, a complication of underlying lung disease.

Primary spontaneous pneumothorax usually presents in young adults and is caused most commonly by apical blebs. Smoking seems to play a considerable role in the development of these blebs. Secondary causes include chronic obstructive pulmonary disease, metastases (primary sarcomas, particularly osteogenic sarcoma), infectious etiologies (tuberculosis, Pneumocystis jiroveci infection), cystic lung disease (pulmonary Langerhans cell histiocytosis and lymphangiomyomatosis), and endometriosis.

CT scan provides a more thorough assessment of the distribution of pleural air. CT may show apical blebs or subpleural metastases as the etiology of the pneumothorax.

Fig.: CT scan of the chest demonstrates left pneumothorax (asterix). Small blebs are observed at the lung apex (arrows), which suggest the underlying the causative factor. ***References:*** J. F. Costa; Radiology, Hospitais da Universidade de Coimbra, Coimbra, PORTUGAL

Tension pneumothorax shows a distinct shift of the mediastinum to the contralateral side and flattening or inversion of the ipsilateral hemidiaphragm. A tension pneumothorax usually results in cardiopulmonary compromise (shock, bradycardia, hypoxia) and requires immediate needle decompression (thoracentesis).

5) Pneumomediastinum

Pneumomediastinum or migration of air into the mediastinum generally results from extrathoracic (ie, iatrogenic, penetrating trauma) or intrathoracic causes (ie, alveolar rupture, Valsalva maneuver, tracheal rupture, esophageal rupture, or blunt trauma). Spontaneous pneumomediastinum has been described with rupture of pleural blebs, marijuana or cocaine inhalation, labor, respiratory infection, emesis, and athletic competition.

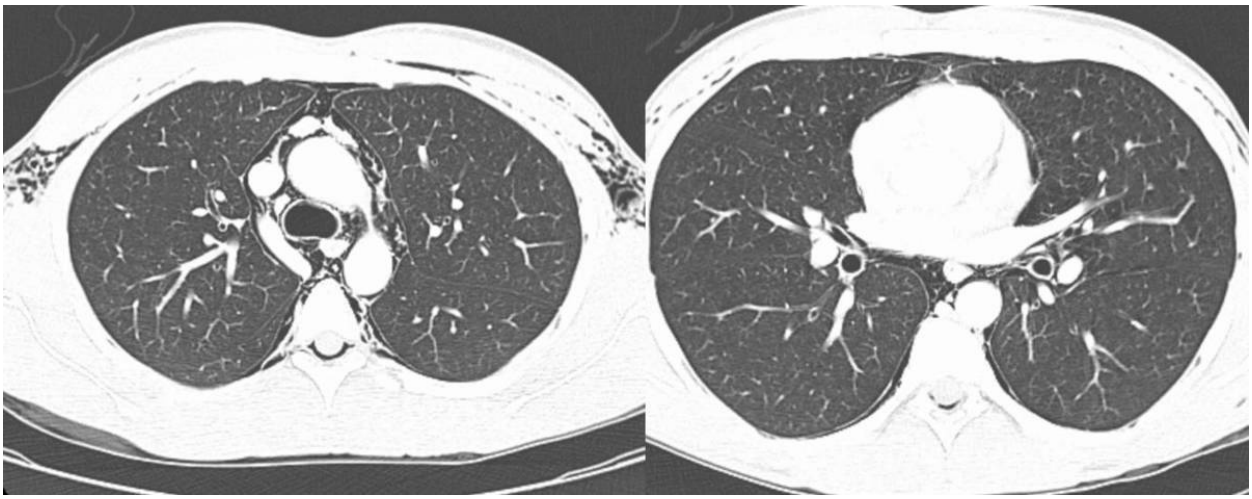

Fig.: Axial CT images with lung windows demonstrate subcutaneous emphysema in the anterior chest wall and significant gas surrounding all of the mediastinal structures and both main bronchi, which is compatible with pneumomediastinum. There is also gas within the spinal canal.
References: J. F. Costa; Radiology, Hospitais da Universidade de Coimbra, Coimbra, PORTUGAL

Esophageal perforation

Esophageal perforation can occur from violent retching (Boerhaave's syndrome) or from trauma (including iatrogenic causes, such as endoscopy).

Fluoroscopic evaluation of the esophagus is the examination of choice; water-soluble contrast is used initially, with the subsequent administration of barium for a more definitive assessment. MDCT has played a greater role in evaluating esophageal rupture because of the ability to elicit an alternative diagnosis while looking for primary and secondary signs of rupture. Findings that raise suspicion for esophageal injury include mediastinal gas or fluid, esophageal thickening, or pleural effusion, particularly left-sided effusion.

6) Pericarditis

Pericarditis is inflammation of the pericardium. The many causes of pericarditis include collagen vascular disease, renal insufficiency, neoplasm, viral infections, tuberculosis, and bacterial infections. The diagnosis of pericarditis is suspected in the patient who has chest pain, pericardial rub on physical examination, and characteristic ECG changes.

CT and MR imaging may be used to image the pericardium and pericardial space. CT and MR imaging evidence of thickened pericardium, enhancement of the pericardium

that indicates inflammation, and visualization of pericardial effusion support the diagnosis of pericarditis.

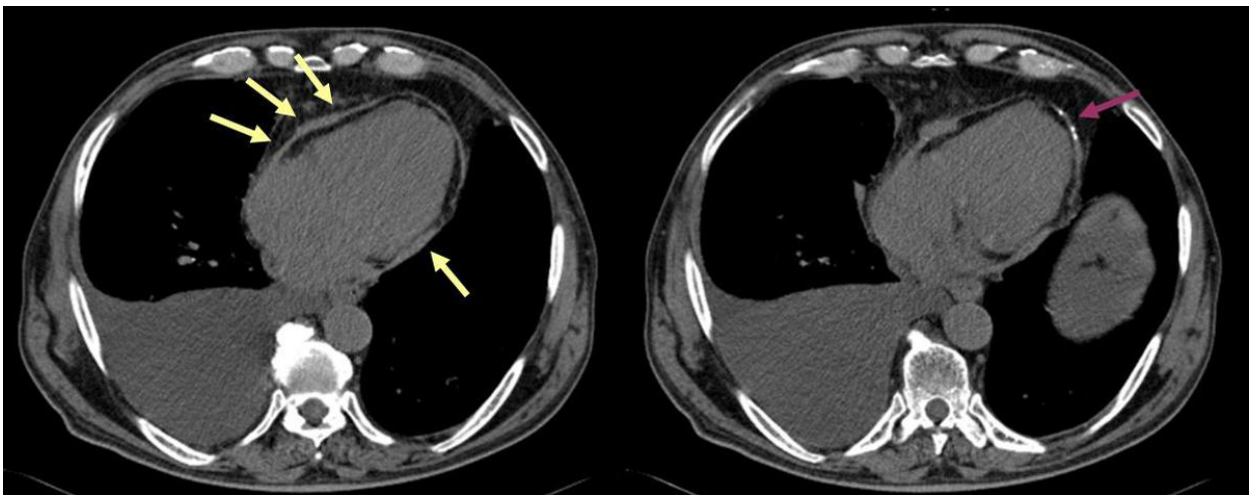

Fig.: Constrictive pericarditis in a 55-year-old man who presented with symptoms of heart failure and chest pain. Axial CT scan shows pericardial thickening (arrows), associated with discrete foci of calcifications in the apical portion (purple arrow).
References: J. F. Costa; Radiology, Hospitais da Universidade de Coimbra, Coimbra, PORTUGAL

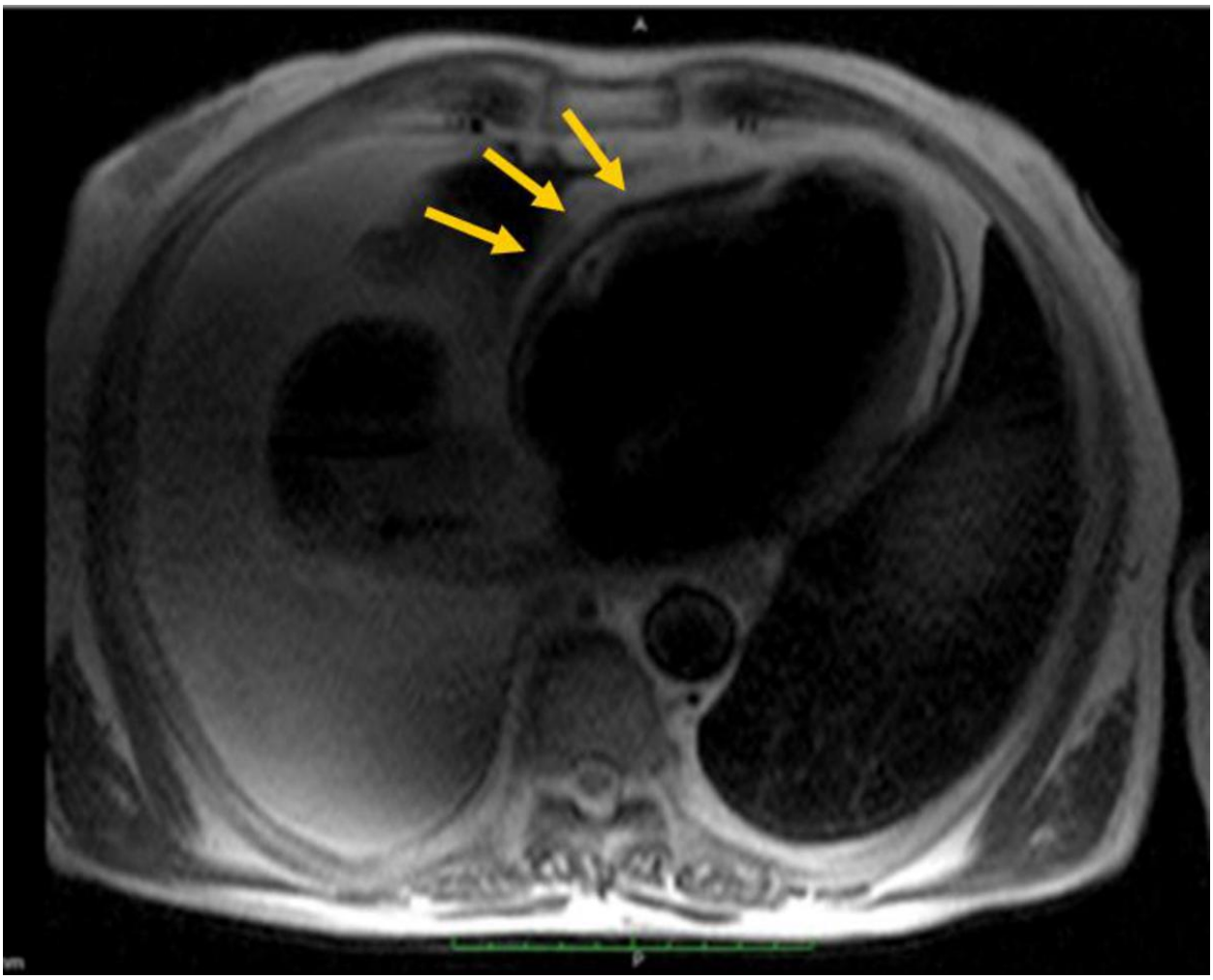

Fig.: Axial ECG-gated HASTE image shows abnormally thickened pericardium (arrows) outlined by epicardial and anterior mediastinal fat.
References: J. F. Costa; Radiology, Hospitais da Universidade de Coimbra, Coimbra, PORTUGAL

7) <u>Pneumonia</u>

Despite advances in diagnosis and treatment, pulmonary infections remain a major cause of morbidity and mortality in adult patients.

Radiology plays a prominent role in the evaluation of pneumonia. Chest radiography is the most commonly used imaging tool in pneumonias, because of its availability and excellent cost/benefit ratio. CT should be used in unresolved cases or when complications of pneumonia are suspected.

The classic classification of pneumonias into lobar and bronchial types has been abandoned for a more clinical classification. Thus, bacterial pneumonias are divided

into three main groups: community-acquired pneumonia, aspiration pneumonia, and nosocomial pneumonia. The usual pattern of community-acquired pneumonia is that of lobar pneumonia: an air-space consolidation that is limited to one lobe or segment.

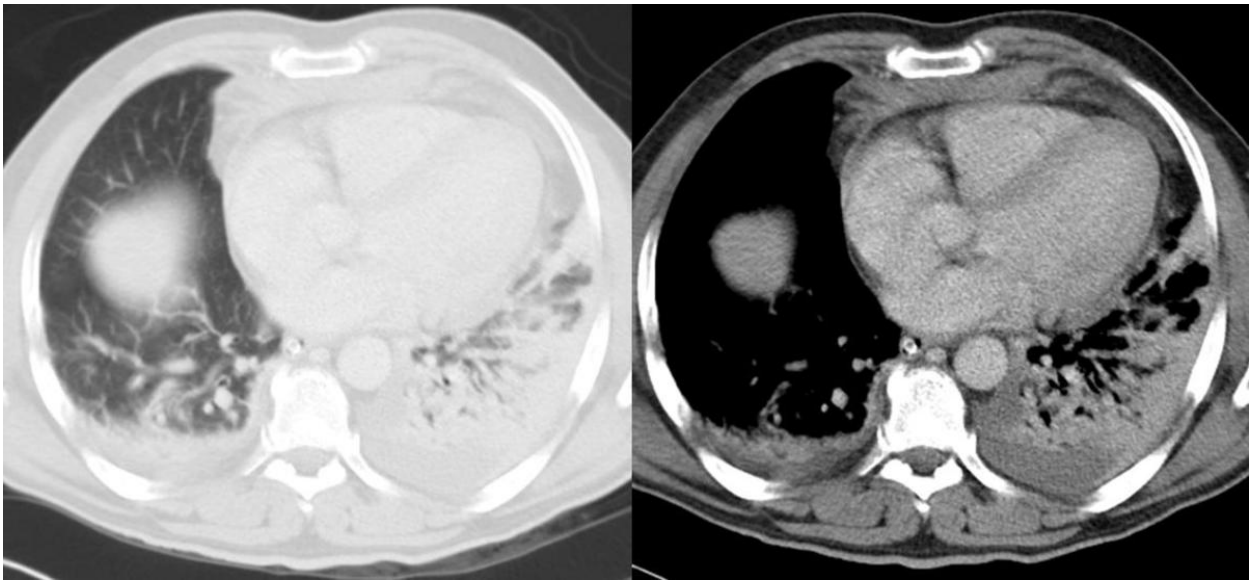

Fig.: Streptococcus pneumonia. CT scan of the chest demonstrates confluent opacification of left lower lobe, with air-bronchograms, in addition to bilateral pleural effusions.
References: J. F. Costa; Radiology, Hospitais da Universidade de Coimbra, Coimbra, PORTUGAL

Aspiration pneumonia generally involves the lower lobes, with bilateral multicentric opacities. Several investigative teams have concluded that no radiologic features exist that can be used to differentiate between viral pneumonia from bacterial pneumonia.

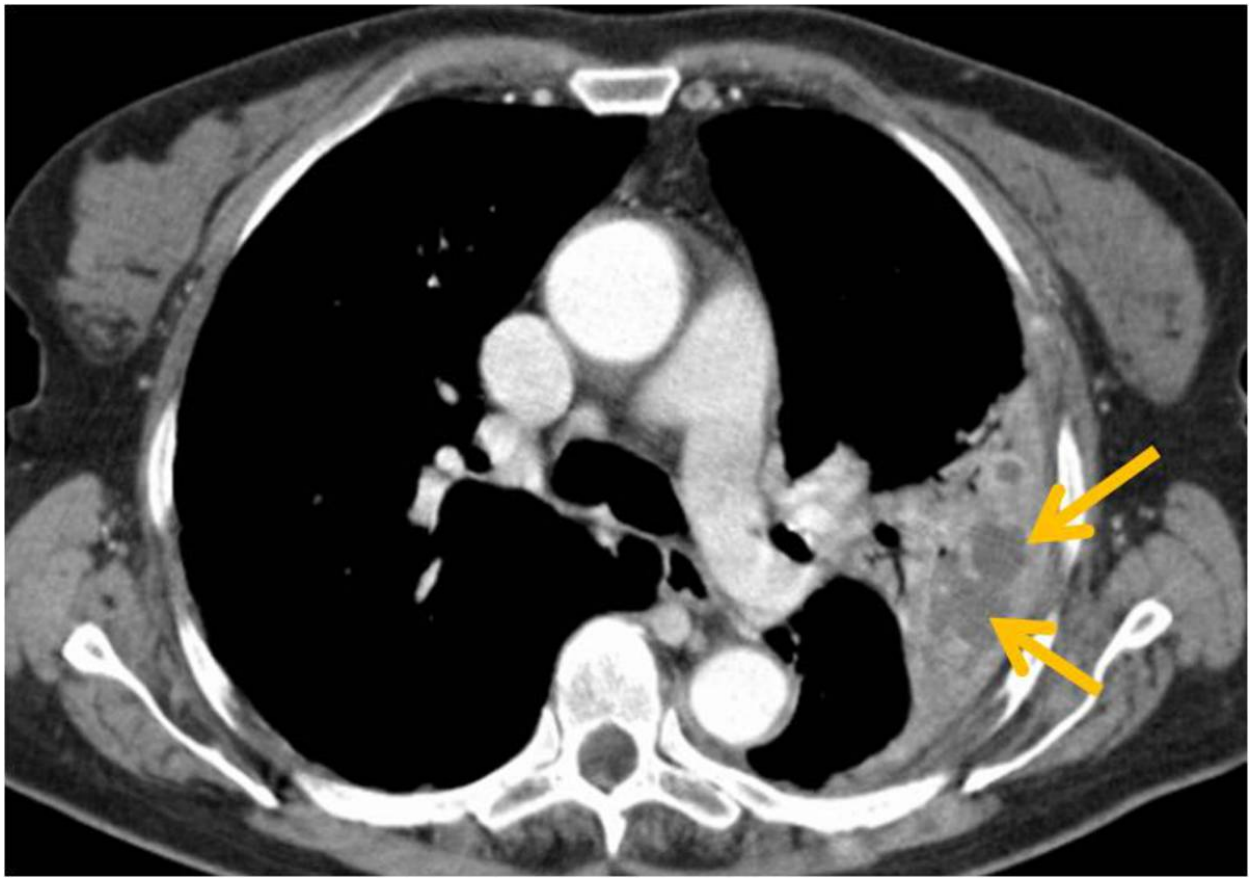

Fig.: Staphylococcus pneumonia. CT scan of the chest demonstrates consolidation in the left upper lobe (apical-posterior segment) containing a focal regions of low attenuation (arrows) consistent with necrosis.
References: J. F. Costa; Radiology, Hospitais da Universidade de Coimbra, Coimbra, PORTUGAL

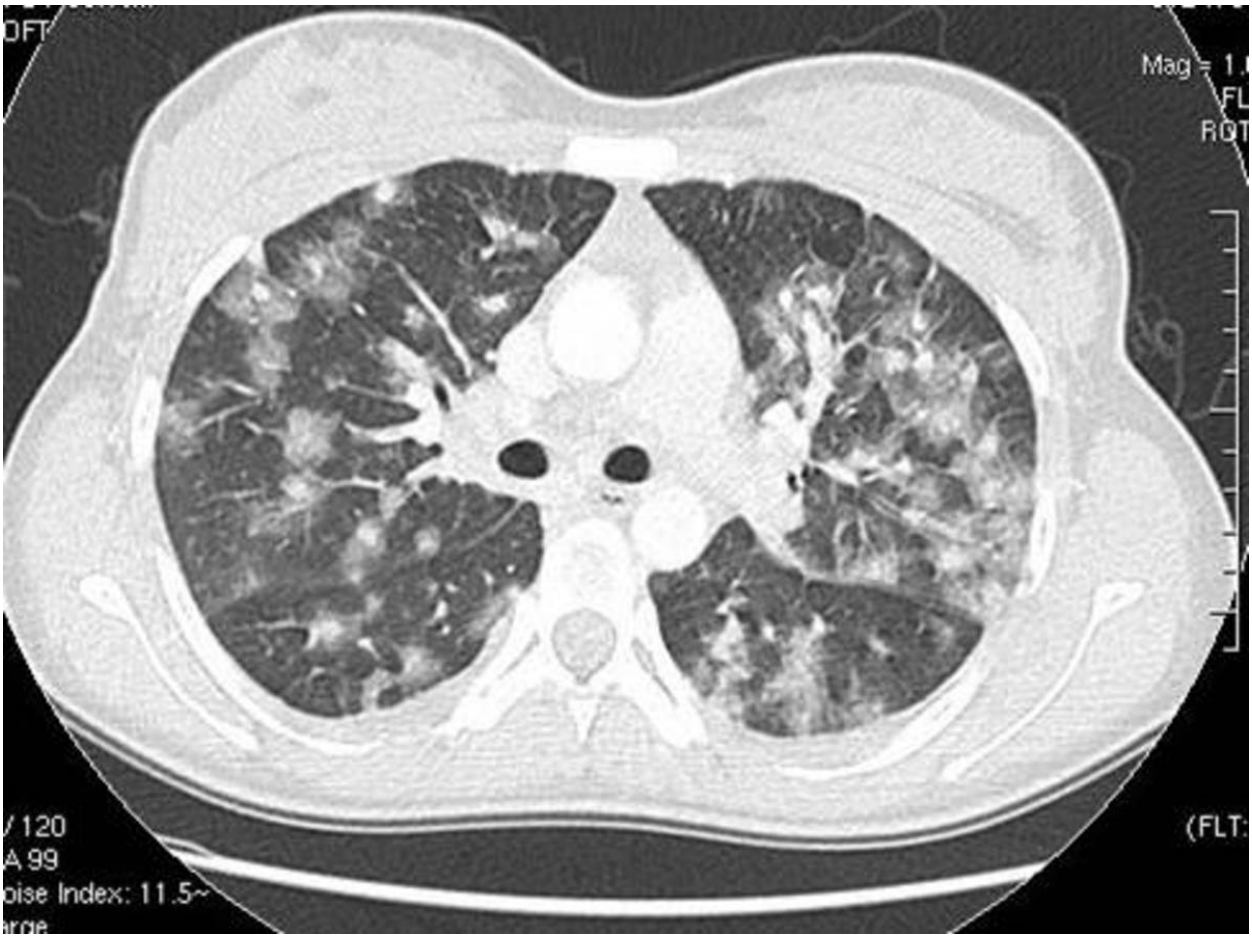

Fig.: Influenzae pneumonia. CT scan of the chest demonstrates multifocal nodular opacities with halo sign.
References: J. F. Costa; Radiology, Hospitais da Universidade de Coimbra, Coimbra, PORTUGAL

Pneumocystis jiroveci pneumonia

Although the radiographic findings in patients who have Pneumocystis jiroveci pneumonia vary, most chest radiographs reveal bilateral, symmetric, fine to medium reticular heterogeneous opacities. As the disease worsens, the opacities coalesce and eventually appear as a bilateral homogeneous consolidation. The presence of hilar or mediastinal adenopathy as well as pleural fluid is rare and suggests another disease process.

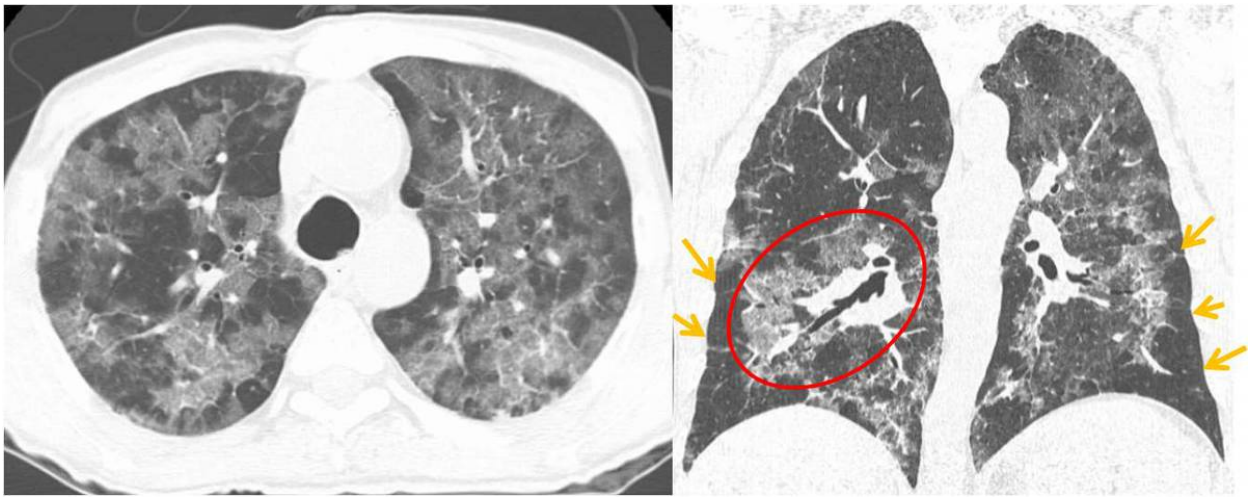

Fig.: PCJ pneumonia in a young HIV-positive patient. CT scan demonstrates predominantly central (circle) airspace disease of ground glass attenuation with relative peripheral sparing (arrows).
References: J. F. Costa; Radiology, Hospitais da Universidade de Coimbra, Coimbra, PORTUGAL

Conclusion

The paramount challenge in the assessment of a patient with chest pain is to distinguish between life-threatening and comparatively benign causes of pain. Potentially life-threatening conditions include aortic dissection and pulmonary embolism, but by far the most important of them is the acute coronary syndrome.

MDCT allows rapid, cost-effective evaluation of patients with acute chest pain. Tailoring the examination to the working clinical diagnosis can markedly improve diagnostic accuracy. Clear communication between the radiologist, the patient, and the referring physician is essential for narrowing the differential diagnosis into a working diagnosis prior to MDCT.

Personal Information

João Filipe Costa, MD

joaofilipegmc@sapo.pt

Hospitais da Universidade de Coimbra

Faculdade de Medicina da Universidade de Coimbra

Portugal

References

Eva Castaner e tal. CT in Nontraumatic Acute Thoracic Aortic Disease: Typical and Atypical Features and Complications. RadioGraphics 2003**;** 23:S93-S110

Udo Hoffmann e tal. Cardiac CT in Emergency Department Patients with Acute

Chest Pain. RadioGraphics 2006; 26:963-980

Zhen J. Wang et al. CT and MR Imaging of Pericardial Disease. RadioGraphics 2003; 23:S167-S180

Kenneth H. Butler and Sharon A. Swencki. Chest Pain: A Clinical Assessment. Radiol Clin N Am 44 (2006) 165-179

Paul G. Kluetz and Charles S. White. Acute Pulmonary Embolism: Imaging in the Emergency Department. Radiol Clin N Am 44 (2006) 259-271

Jean Jeudy, Stephen Waite, and Charles S. White. Nontraumatic Thoracic Emergencies. Radiol Clin N Am 44 (2006) 273-293

Stephen Waite, Jean Jeudy, and Charles S. White. Acute Lung Infections in Normal and Immunocompromised Hosts. Radiol Clin N Am 44 (2006) 295-315